

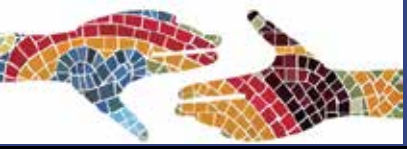# Espondiloartritis:

## Actualització en la interpretació de la ressonància magnètica de sacroilíaqes



**José A. Narváez**

Secció de Radiologia MSQ,  
Hospital Universitari de Bellvitge  
L'Hospitalet de Llobregat



ÍNDICE

CRITERIOS ASAS

DAÑO ESTRUCTURAL

SECUENCIAS DIFUSIÓN

CONCLUSIÓN

- 1) Criterios ASAS para la clasificación de EspA axial
  - a) Limitaciones de la definición de RM de SI +
  - b) Definición de RM de SI +: actualización de 2016
- 2) Daño estructural en RM de SI
- 3) Técnicas de difusión (Dwi) en RM de SI: diagnóstico y monitorización
- 4) RM de cuerpo entero (Whole Body MRI) vs RM de SI
- 5) Conclusión

## ASAS Classification Criteria for Axial Spondyloarthritis (SpA)

ÍNDICE

CRITERIOS ASAS

DAÑO ESTRUCTURAL

SECUENCIAS DIFUSIÓN

CONCLUSIÓN

In patients with  $\geq 3$  months back pain and age at onset  $< 45$  years

Sacroiliitis on Imaging\*  
Plus  
 $\geq 1$  SpA features\*\*

OR

HLAB-27  
Plus  
 $\geq$  other SpA features\*\*

Sensitivity = 82.0%, Specificity = 84,4%

Imaging alone:  
Sensitivity = 66.2%, Specificity = 97.3%

# ASAS CRITERIA: Clinical Arm

## ASAS Classification Criteria for Axial Spondyloarthritis (SpA)

ÍNDICE

CRITERIOS ASAS

DAÑO ESTRUCTURAL

SECUENCIAS DIFUSIÓN

CONCLUSIÓN

In patients with  $\geq 3$  months back pain and age at onset  $< 45$  years

### \*\*SpA features

- inflammatory back pain
- arthritis
- enthesitis (heel)
- uveitis
- dactylitis
- psoriasis
- Crohn's disease
- good response to NSAIDs
- family history of SpA
- HLA-B27
- Elevated CRP

HLAB-27

Plus

$\geq$  other SpA features\*\*

## ASAS Classification Criteria for Axial Spondyloarthritis (SpA)

In patients with  $\geq 3$  months back pain and age at onset  $< 45$  years

ÍNDICE

CRITERIOS ASAS

DAÑO ESTRUCTURAL

SECUENCIAS DIFUSIÓN

CONCLUSIÓN

Sacroiliitis on Imaging\*  
Plus  
 $\geq 1$  SpA features\*\*

OR

HLAB-27  
Plus  
 $\geq$  other SpA features\*\*

\*\* SpA features

- inflammatory back pain
- arthritis
- enthesitis (heel)
- uveitis
- dactylitis
- psoriasis
- Crohn's disease
- good response to NSAIDs
- family history of SpA
- HLA-B27
- Elevated CRP

Sacroiliitis on Imaging:

- Active (acute) inflammation in MRI
- Radiological sacroiliitis defined according to the New York Criteria (grade  $> 2$  bilateral or grade 3-4 unilateral)

# ASAS CRITERIA: Imaging Arm

## ASAS Classification Criteria for Axial Spondyloarthritis (SpA)

In patients with  $\geq 3$  months back pain and age at onset  $< 45$  years

Sacroiliitis on Imaging\*  
Plus  
 $\geq 1$  SpA features\*\*

### Sacroiliitis on Imaging:

- Active (acute) inflammation in MRI
- Radiological sacroiliitis defined according to the New York Criteria (grade  $> 2$  bilateral or grade 3-4 unilateral)

### Radiographic grading of SI changes in AS

- |         |  |
|---------|--|
| Grade 0 | Normal   |
| Grade 1 | Suspicious   |
| Grade 2 | Sclerosis, some erosions                                     |
| Grade 3 | Severe erosions, widening of the joint space, some ankylosis |
| Grade 4 | Complete ankylosis   |



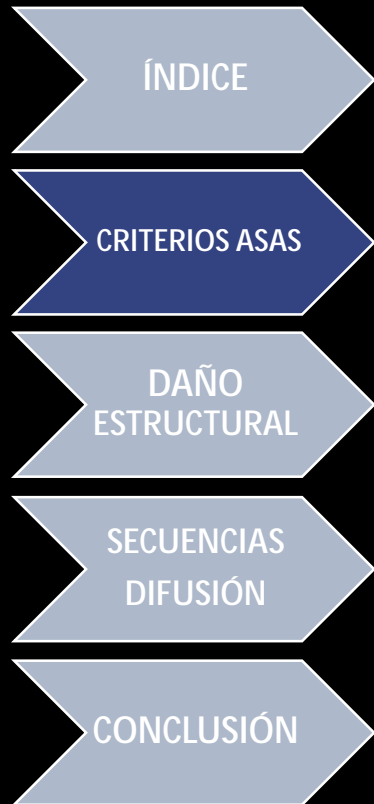ÍNDICE

CRITERIOS ASAS

DAÑO ESTRUCTURAL

SECUENCIAS DIFUSIÓN

CONCLUSIÓN



## Active (acute) inflammation in MRI

- The presence of active lesions at the SI joints (“active sacroiliitis”) is needed to meet the criterion of “positive MRI for sacroiliitis”
- Bone marrow edema (Fat Supressed T2/STIR) or osteitis (FS-T1-Gd) is suggestive of SpA as long as they affect the subchondral and periarticular areas of bone marrow
- **Amount of signal required:**
  - a) If there is only one active lesion (bone edema/osteitis) per MRI slice, the lesion should be present on at least two consecutive slices
  - b) If there is more than one signal (lesion) on a single slice, one slice may be sufficient

# ASAS CRITERIA: Imaging Arm

MR imaging of Active sacroiliitis according to the ASAS Criteria

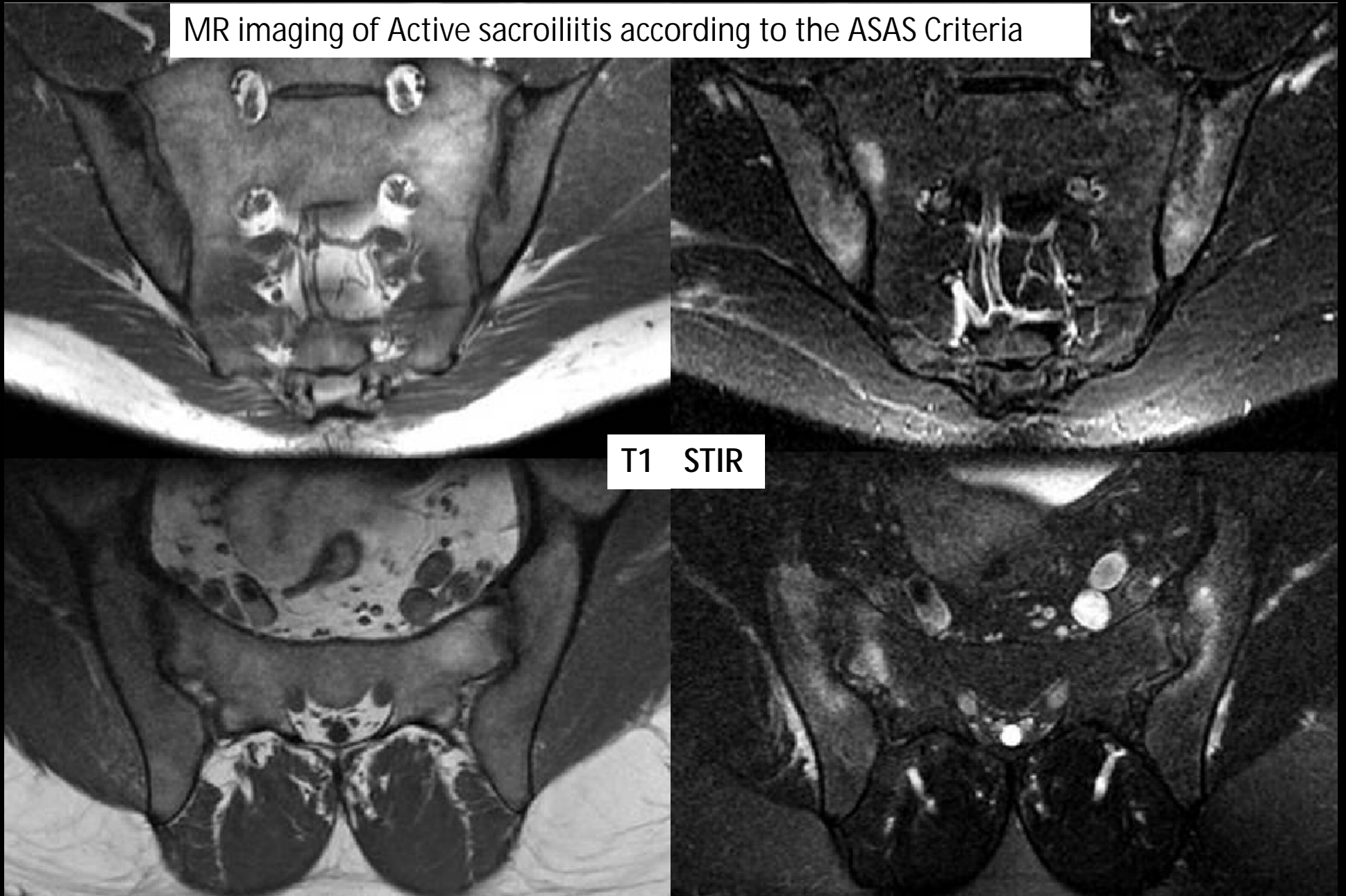
ÍNDICE

CRITERIOS ASAS

DAÑO ESTRUCTURAL

SECUENCIAS DIFUSIÓN

CONCLUSIÓN



T1 STIR





## Other MRI findings

- The isolated existence of other active inflammatory lesions (synovitis, enthesitis or capsulitis) without bone edema/osteitis is **NOT enough to meet the criterion** according to the definition of active sacroiliitis on MRI
- Structural lesions (fat deposition, erosions, sclerosis or ankylosis) probably reflect prior inflammation; however, its presence is **NOT enough to meet the criterion** according to the definition of active sacroiliitis on MRI

ÍNDICE

CRITERIOS ASAS

DAÑO  
ESTRUCTURAL

SECUENCIAS  
DIFUSIÓN

CONCLUSIÓN

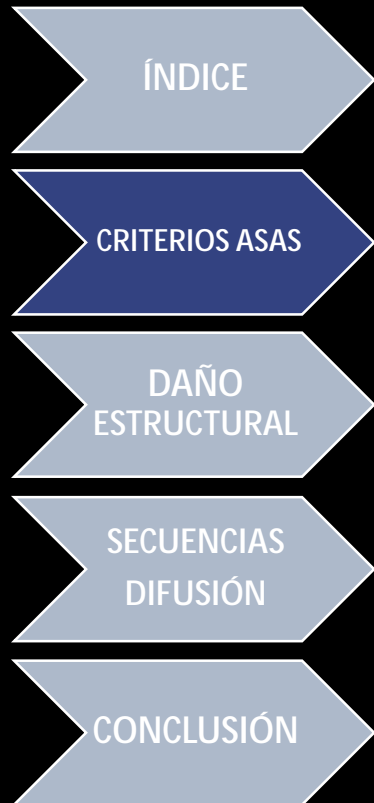- Estudio multicéntrico de casos-contróles para valorar la utilidad de la RM de SI en la diferenciación entre a) pacientes con EspA de B) casos con lumbalgia no específica y c) de voluntarios sanos.
- Todos los grupos tenían  $\leq 45$  años:

Grupos de estudio	Nº pacientes	RM+ por crit ASAS
EA (Rx Crit. NY)	75	64 (85,3%)
Lumbalgia inflamatoria (crit. de Calin o de Berlin)	27	18 (66,7%)
Lumbalgia mecánica	29	6 (23,1%)
Voluntarios sanos	59	4 (6,8%)

- *The pathophysiologic basis of these acute and structural MR changes remains speculative; the most likely explanations may be mechanically induced signal alterations or degenerative changes. "*

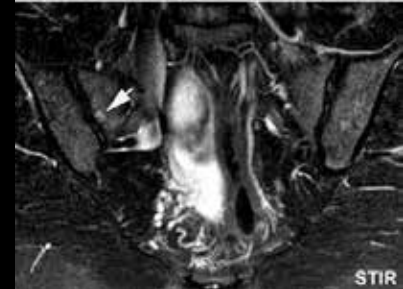
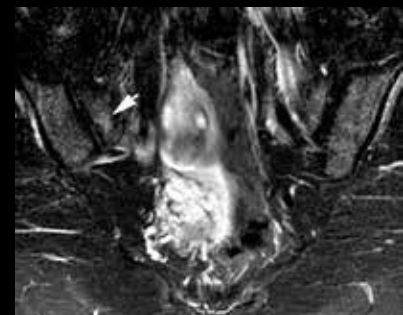
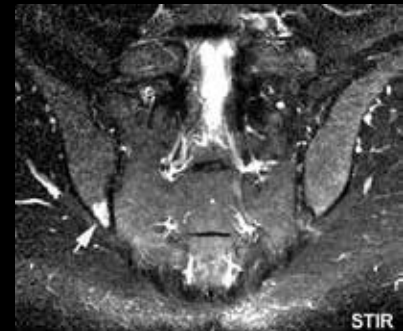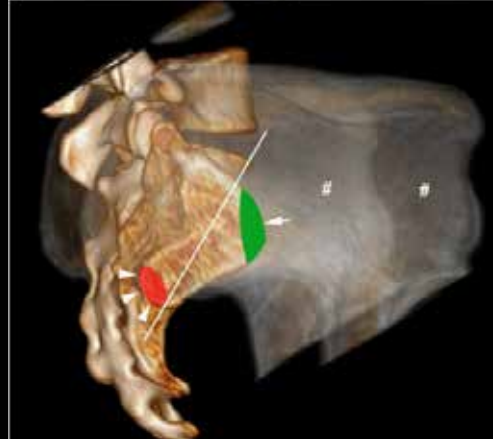
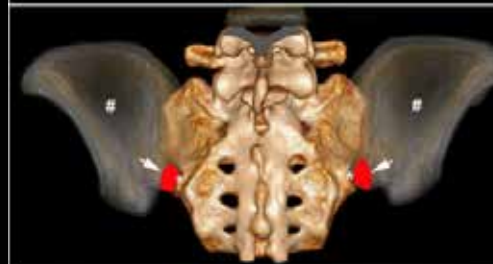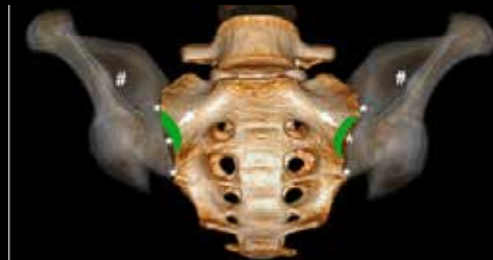
\* Weber U et al. Ann Rheum Dis 2018

\*\* Varkas G et al. Rheumatol 2017;57:588



Grupos de estudio	Nº de pac.	RM + crit ASAS
<b>*Corredores recreacionales:</b>		
-Antes	20	30%
-Después de correr 6 km	20	35%
<b>*Jugadores profesionales de hockey</b>	22	41%
<b>**Reclutas militares:</b>		
-Antes	22	23%
-Después de 6 sem. de entrenamiento intensivo	22	36%

\*El análisis topográfico de los cambios de edema demuestra una localización más frec.en ilíaco posteroinferior y sacro anterosuperior



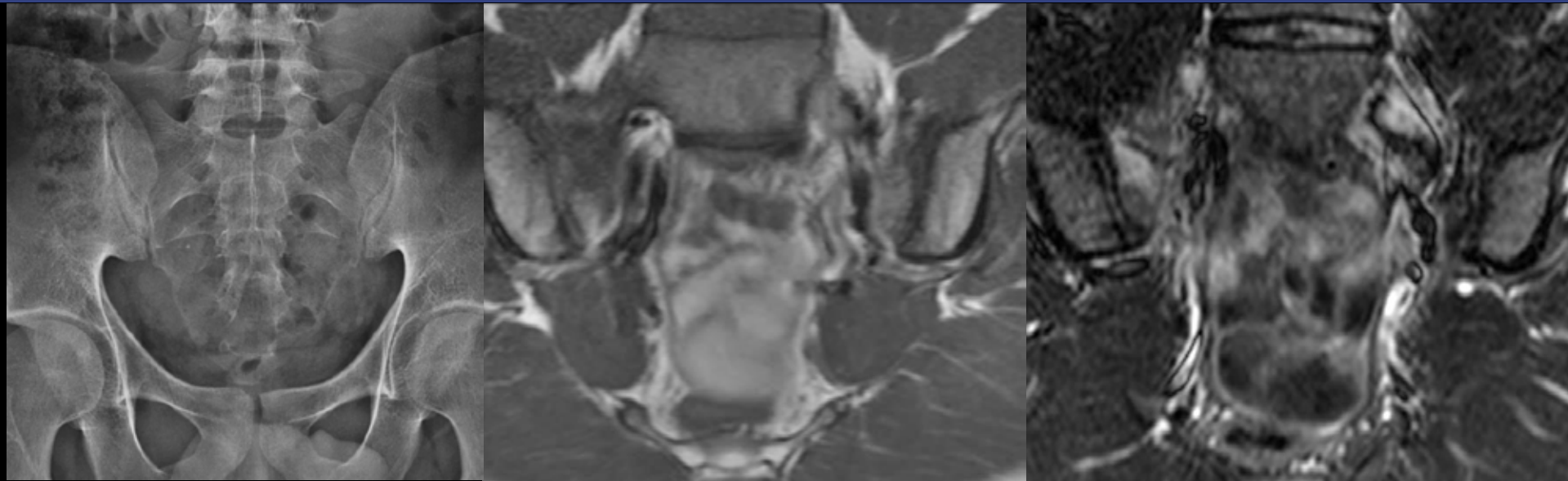
ÍNDICE

CRITERIOS ASAS

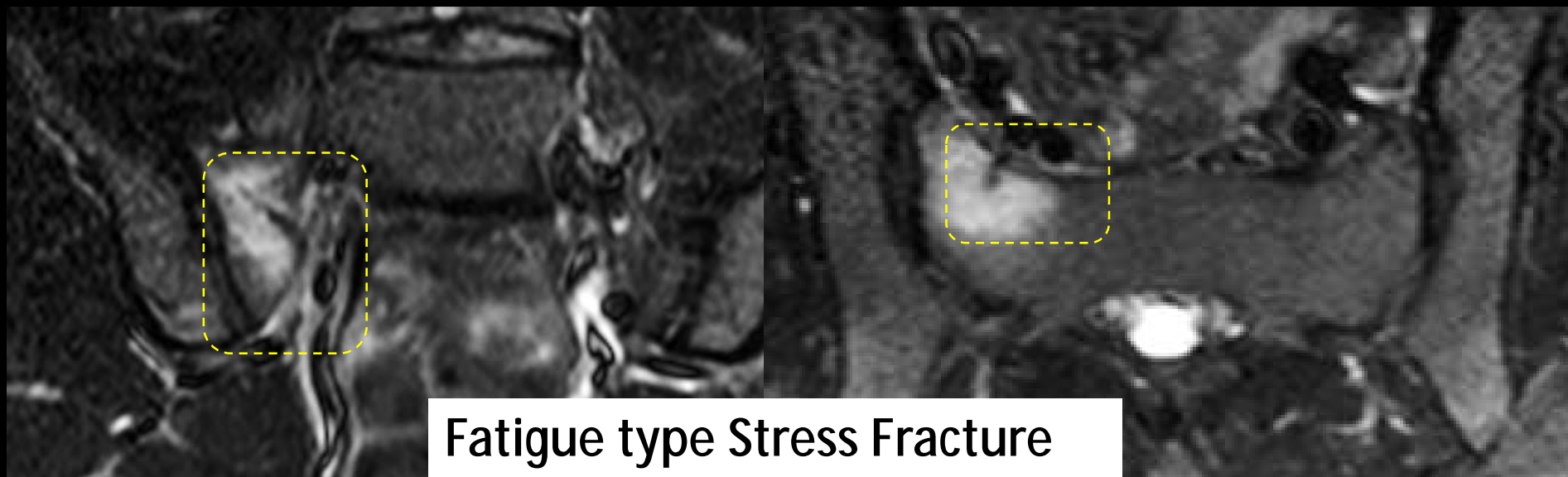
DAÑO  
ESTRUCTURAL

SECUENCIAS  
DIFUSIÓN

CONCLUSIÓN

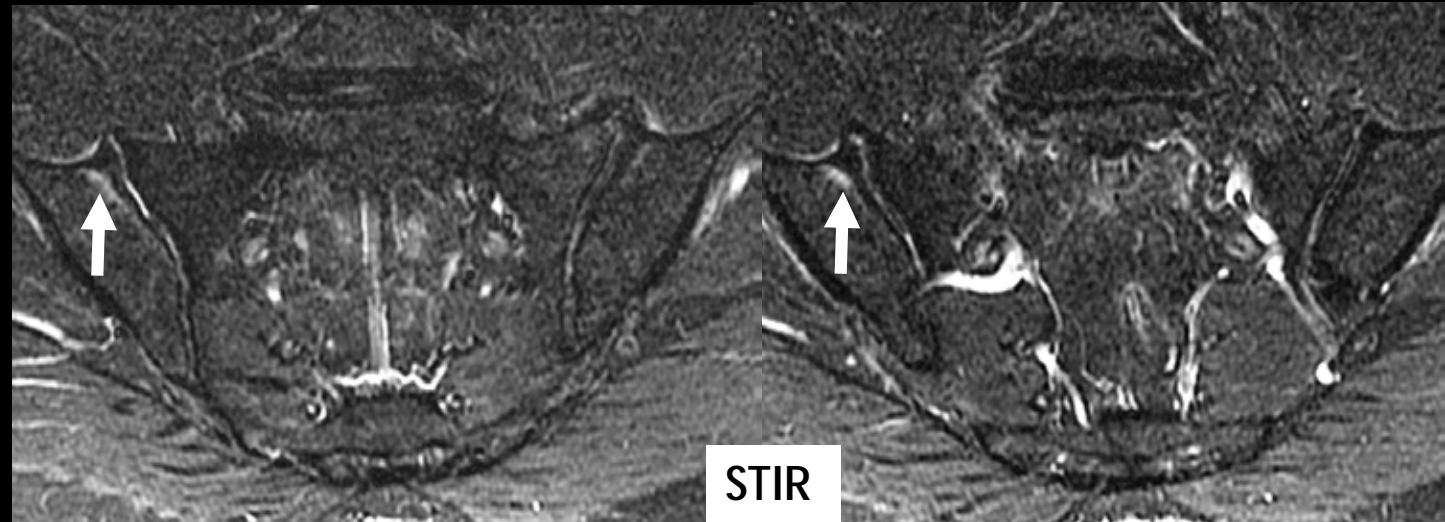


29-year-old man with mechanical low back pain...

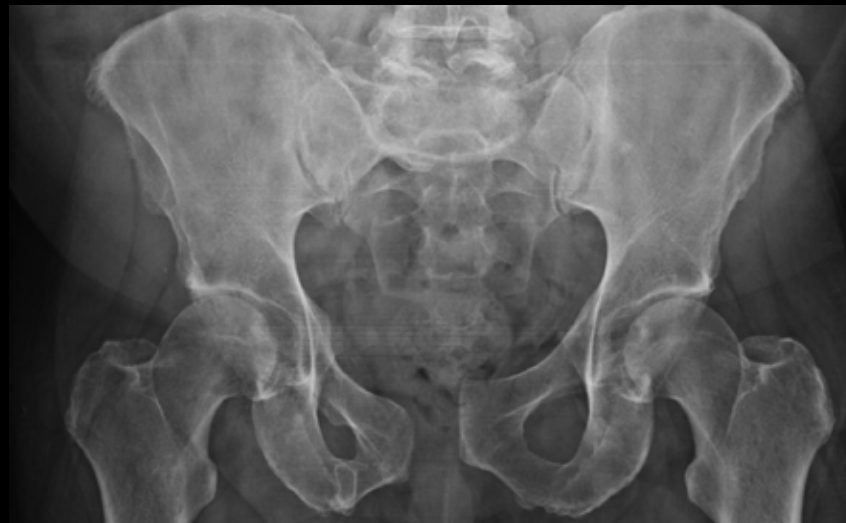

Fatigue type Stress Fracture

A 44 y.o. male with long-standing back pain



MRI show bone edema in two consecutive slices = ASAS +



Patient suffered  
previous Pubic  
Symphysis dislocation

ÍNDICE

CRITERIOS ASAS

DAÑO  
ESTRUCTURAL

SECUENCIAS  
DIFUSIÓN

CONCLUSIÓN

# Sacroiliac Osteoarthritis

- **Osteoarthritis of the SI joints** may present occasionally mild bone marrow edema, subchondral sclerosis, or joint fluid that mimic the MR imaging appearance of sacroiliitis.
- In contrast to sacroiliitis of SpA patients, in sacroiliac osteoarthritis, **sclerotic changes are confined to the subchondral bone and does not extent at more than 5 mm form the SI joint space.**
- Joint fluid in osteoarthritis tends to be more hyperintense than synovitis on T2-WI.

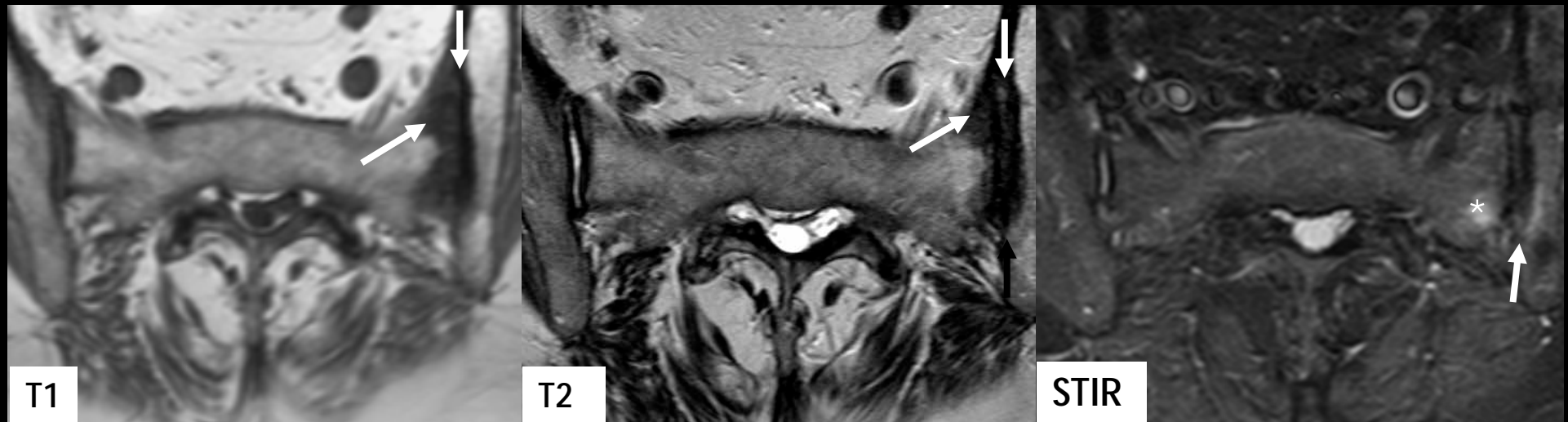
ÍNDICE

CRITERIOS ASAS

DAÑO ESTRUCTURAL

SECUENCIAS DIFUSIÓN

CONCLUSIÓN



Osteoarthritic changes in SI joints, more pronounced in the left side. Oblique axial T1-weighted (a), TSE T2-weighted (b) and STIR (c) images show subchondral sclerosis (arrows) and focal bone marrow edema (asterisk) in the left SI joint. Note hyperintense fluid in the right SI joint space on B.

35 y.o. female with 2 year's history of low back pain. Two areas of subchondral bone edema: ASAS +

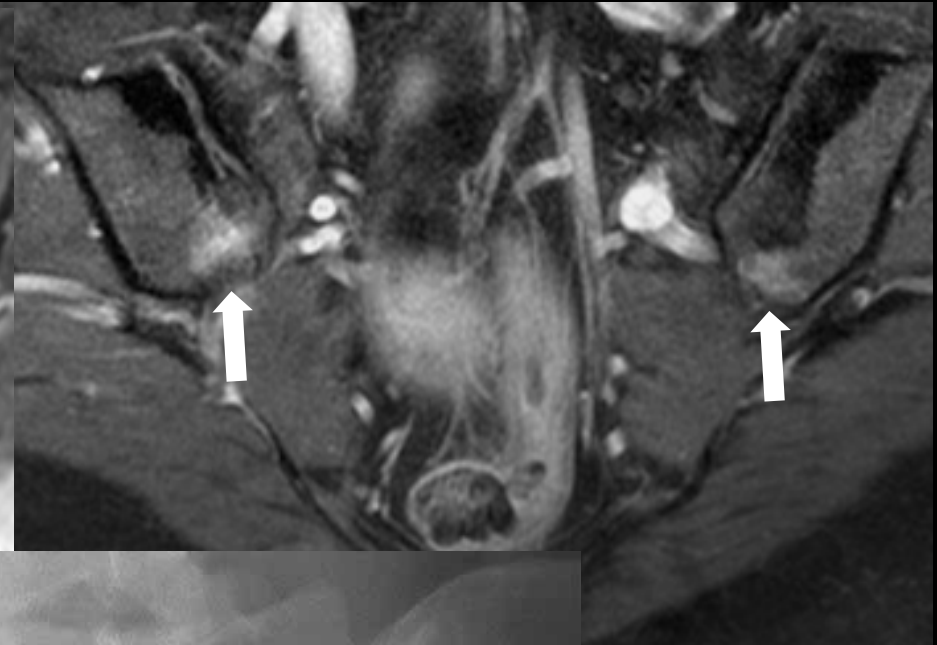
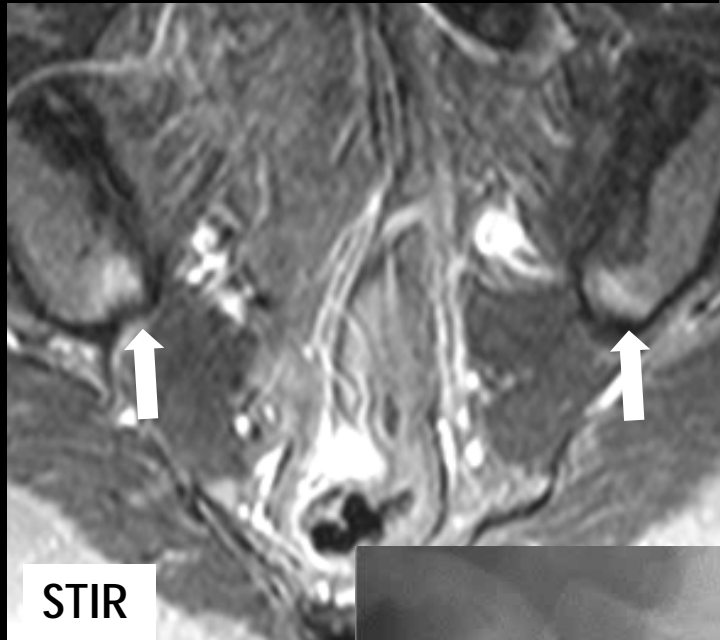
ÍNDICE

CRITERIOS ASAS

DAÑO ESTRUCTURAL

SECUENCIAS DIFUSIÓN

CONCLUSIÓN



Osteitis Condensans Ilii

- It is usually asymptomatic, but uncommonly may cause lower back pain
- OCI is characterized by **benign sclerosis of the ilium adjacent to the SI joint**, typically **bilateral and triangular in shape**
- It is believed to be due to mechanical stress: most often seen in women who have given birth
- **XR**: triangular sclerosis; joint space conserved; it may be unilateral, or involve also the sacral joint
- **MRI**:
  - Triangular low signal intensity
  - Some cases may associate Bone Edema (in some series up to 48% of cases). Those patients tend to be younger and with shorter pain duration
  - Diff. Diagnosis: characteristic location of the triangular, subchondral/periarticular low-signal areas

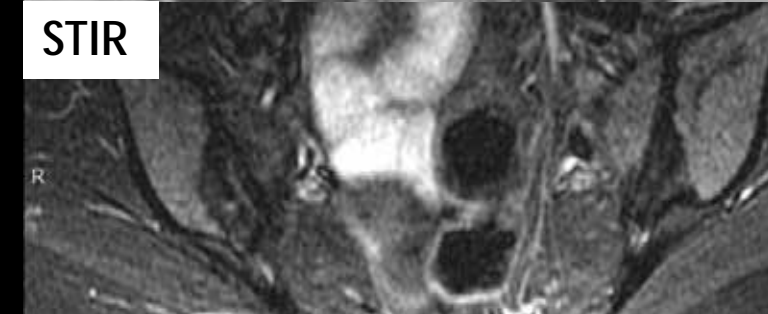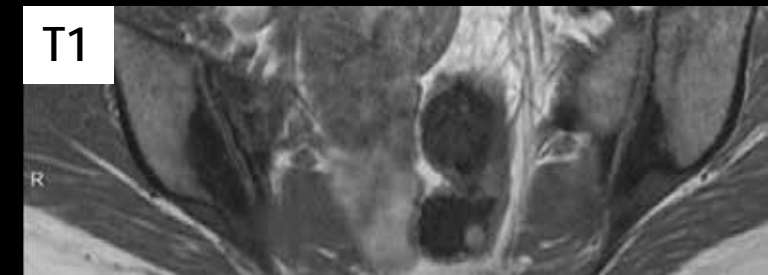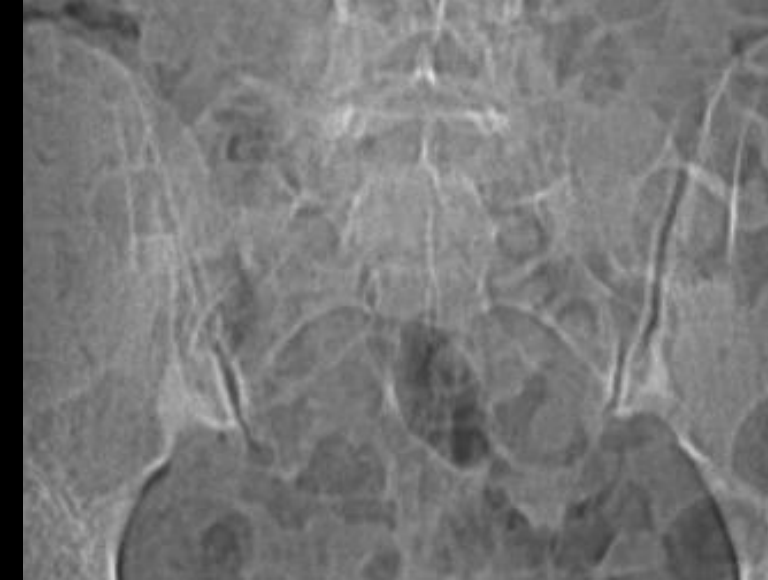
ÍNDICE

CRITERIOS ASAS

DAÑO ESTRUCTURAL

SECUENCIAS DIFUSIÓN

CONCLUSIÓN





- *Phase wrap-around* is a commonly seen MR artifact that occurs whenever the dimensions of an object exceed the defined field-of-view (FOV).
- The wrap-around artifact is generally easily recognized as a folding over of anatomic parts into the area of interest.
- Although this phenomenon may occur in the frequency-encode direction, it is generally more severe along the phase-encode axis.

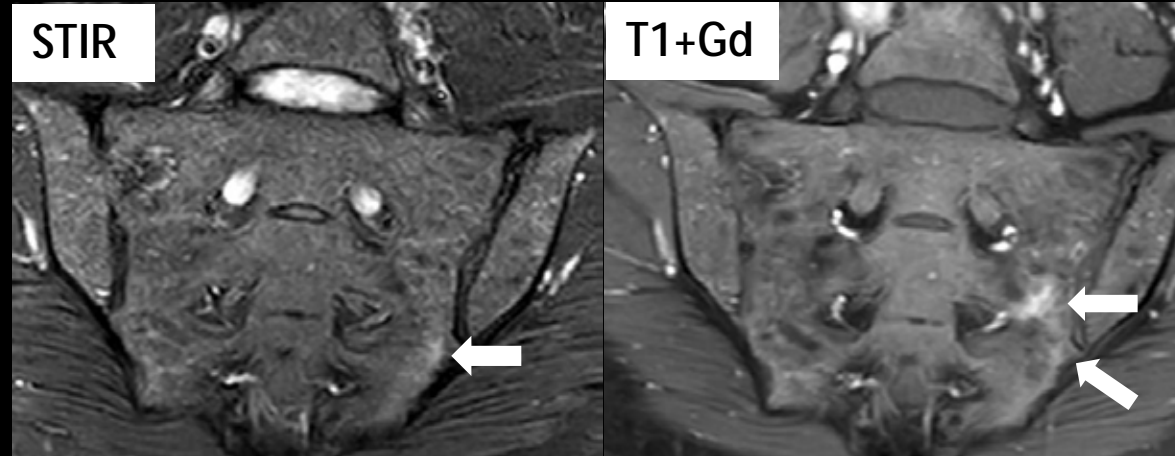
ÍNDICE

CRITERIOS ASAS

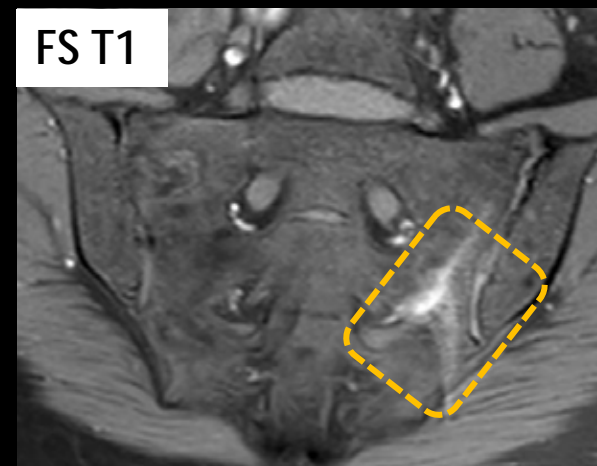
DAÑO ESTRUCTURAL

SECUENCIAS DIFUSIÓN

CONCLUSIÓN



41-y.o. female. MRI initially readed as "subchondral bone edema" with periarticular enhancement in the left SI joint



Fat Supressed T1WI better demonstrates the "wrap-around" artifact, which explains the false hyperintensity on STIR an Gd-T1 WI.

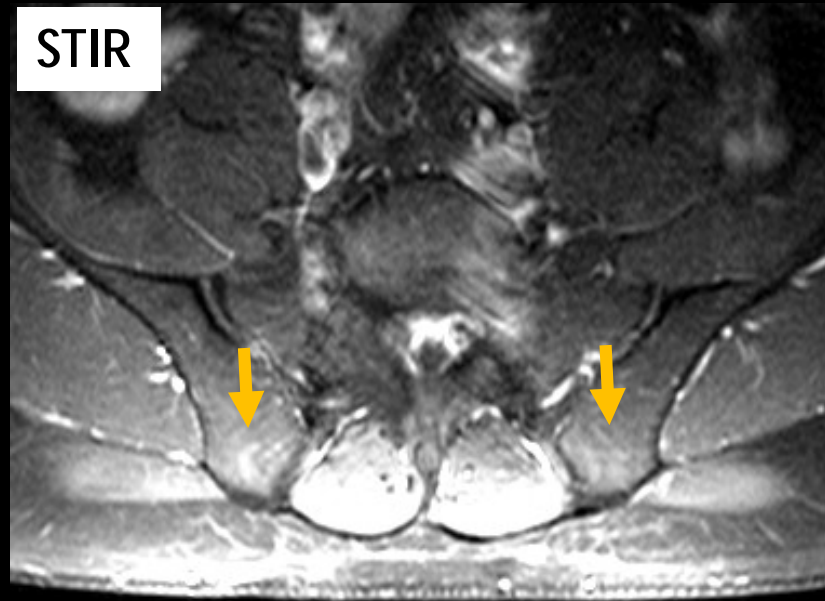
ÍNDICE

CRITERIOS ASAS

DAÑO  
ESTRUCTURAL

SECUENCIAS  
DIFUSIÓN

CONCLUSIÓN



- Coil artifacts may mimic foci of hyperintensity, mainly in the posterior region of the SI joints.
- Careful assessment of contiguous soft tissues and comparison with images in other pulse sequence allow identification of these artifacts

43-year-old man inflammatory low back pain started 1 month after.

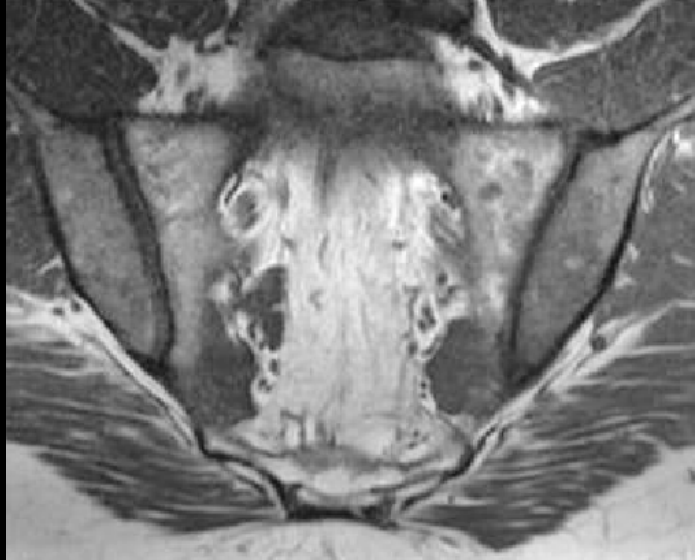ÍNDICE

CRITERIOS ASAS

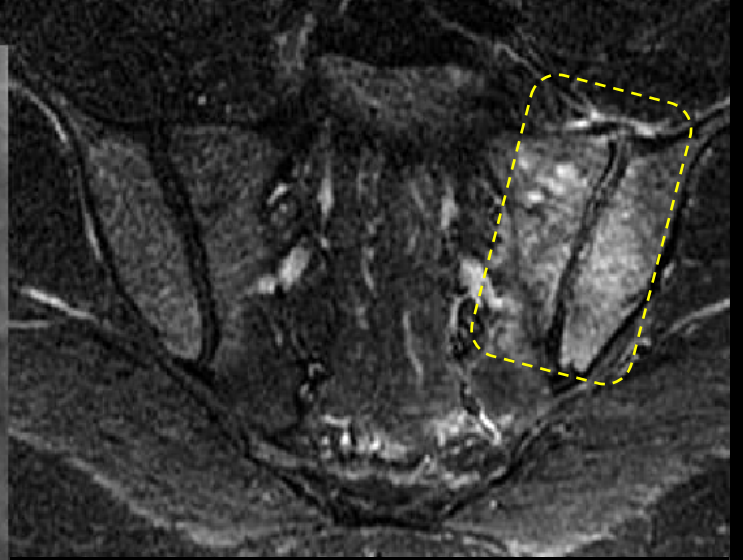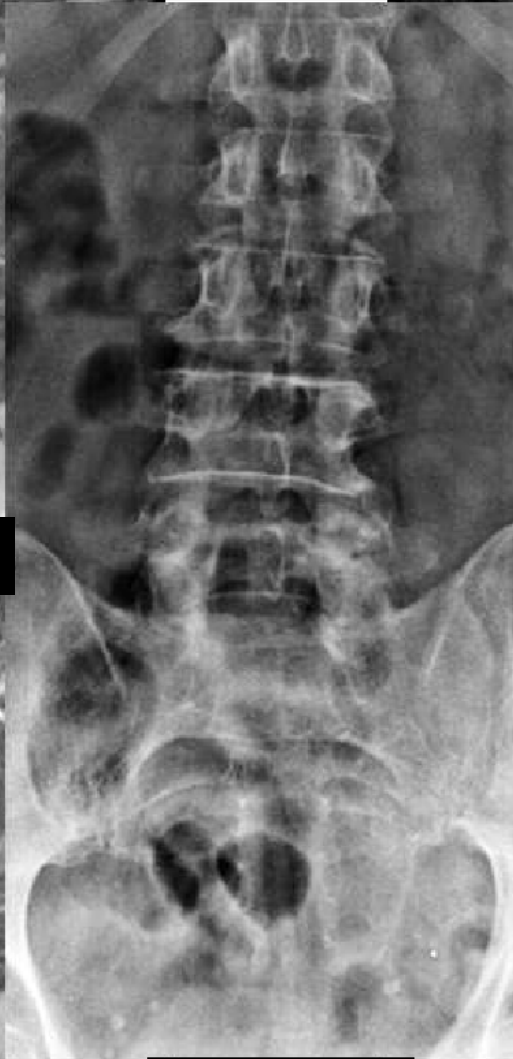DAÑO  
ESTRUCTURAL

SECUENCIAS  
DIFUSIÓN

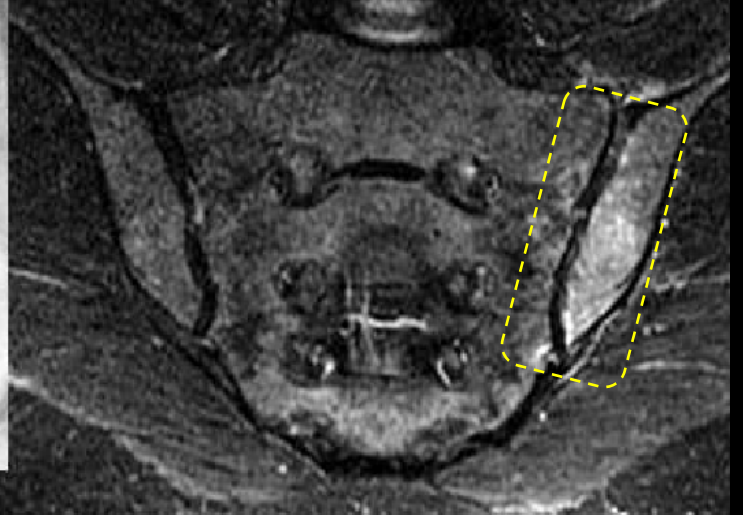
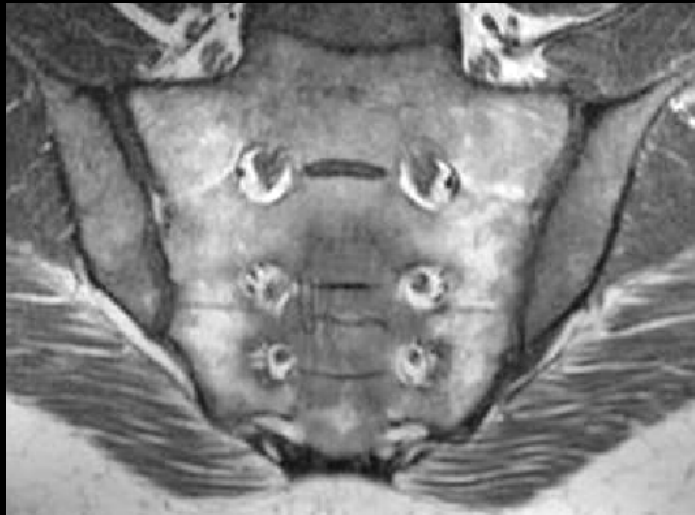
CONCLUSIÓN



T1

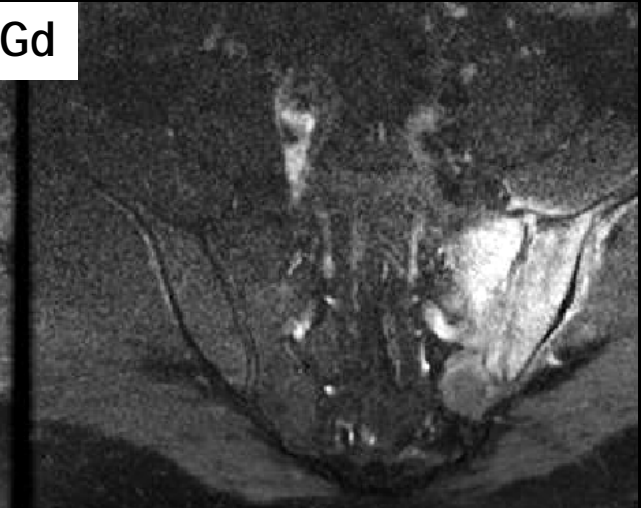
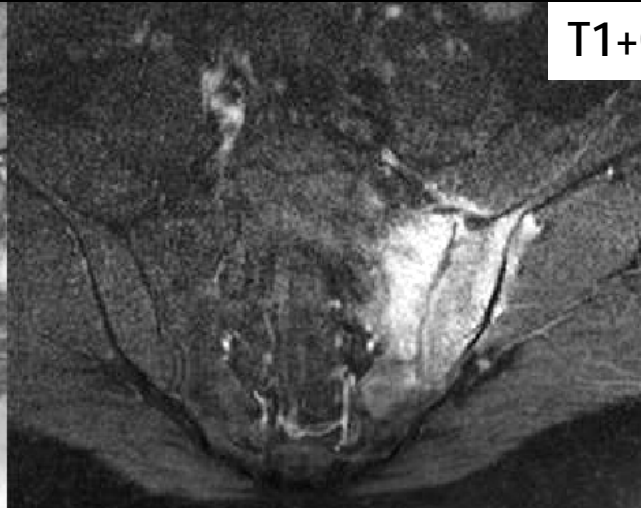
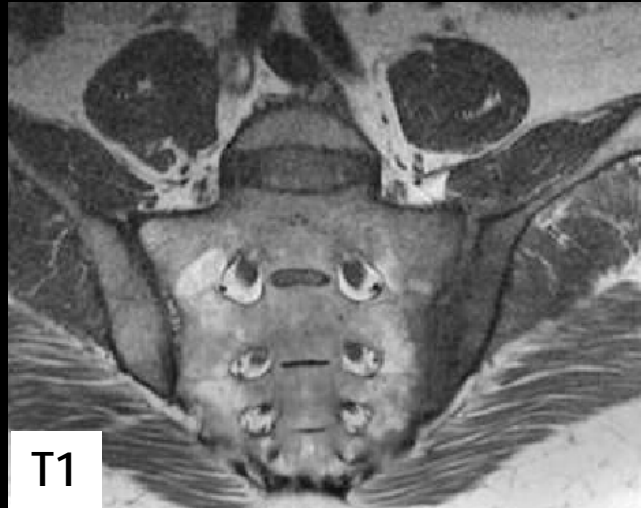

STIR

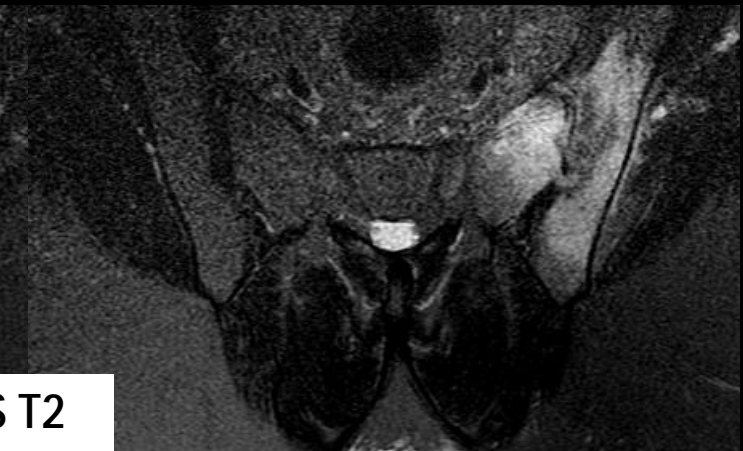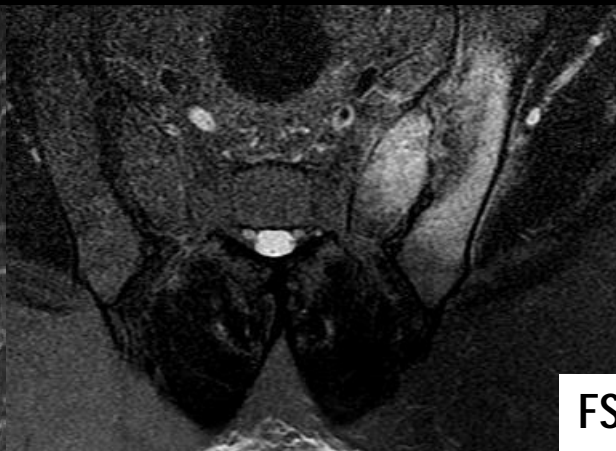
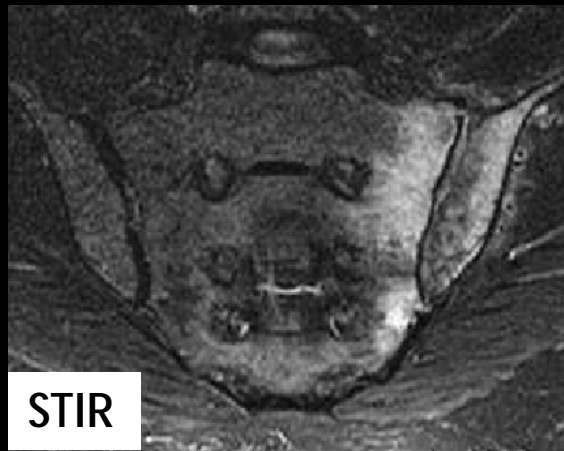


# Infectious Sacroiliitis

3 weeks after...



**Septic arthritis of the left SI joint:** Synovitis, bone marrow edema and erosions are common in both entities, but Septic Sacroiliitis is usually unilateral, and inflammatory changes tends to extend to periarticular soft-tissues.



ÍNDICE

CRITERIOS ASAS

DAÑO ESTRUCTURAL

SECUENCIAS DIFUSIÓN

CONCLUSIÓN

# Infectious Sacroiliitis

- Usually unilateral
- Hematogenous spread; intravenous drugs avusers
- **Imaging clues:**
  - Unilateral
  - Involvement of both anterior (synovial) and posterior (ligamentous) parts of the joint
  - Rapidly progressive
  - Soft-tissue extension beyond the articular joint capsule
  - Contrast iv.: identification of periarticular abscesses

ÍNDICE

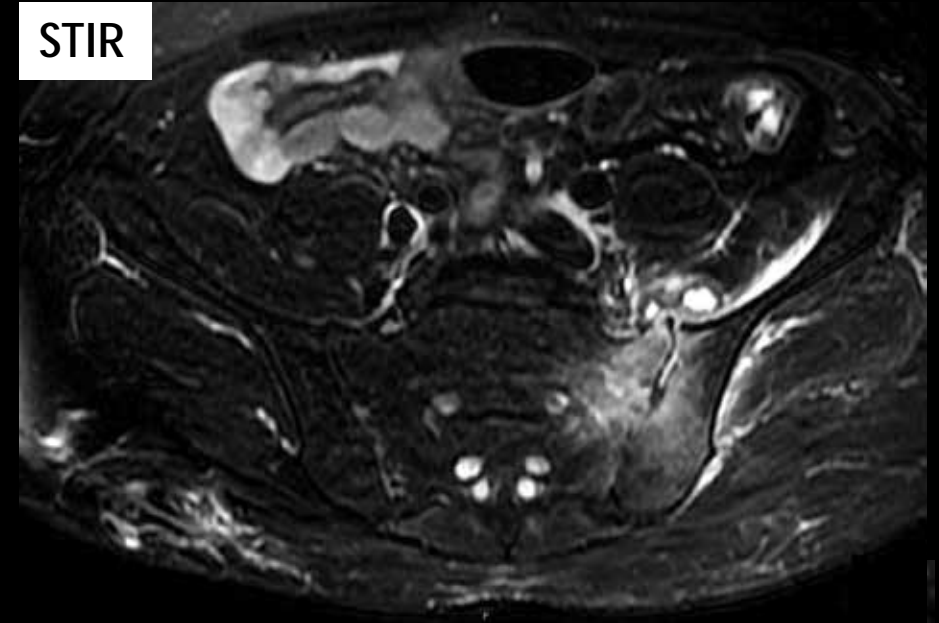
CRITERIOS ASAS

DAÑO ESTRUCTURAL

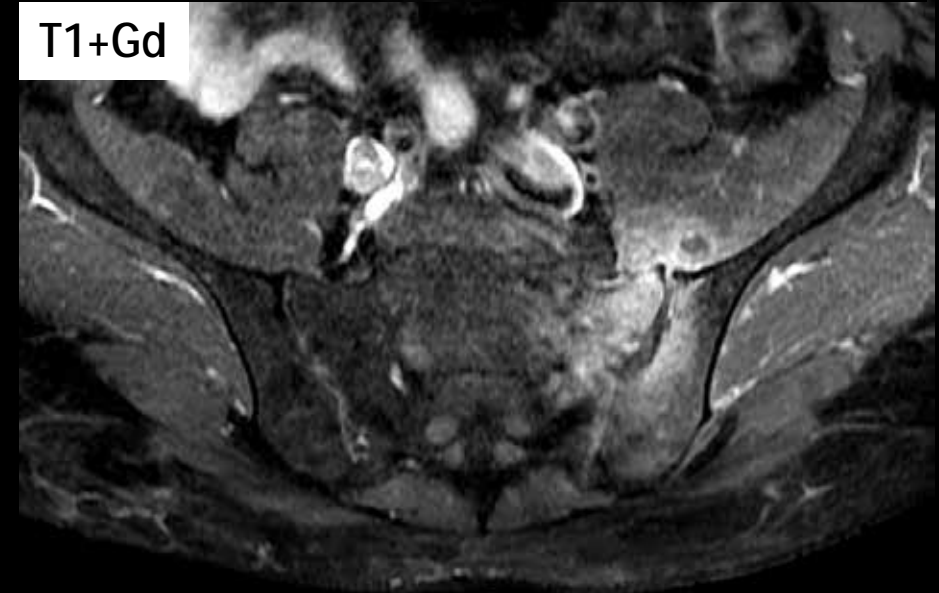SECUENCIAS DIFUSIÓN

CONCLUSIÓN

STIR



T1+Gd



Clinical and epidemiological research  
Extended report

## Defining active sacroiliitis on MRI for classification of axial spondyloarthritis: update by the ASAS MRI working group

Robert G W Lambert<sup>1</sup>, Pauline A C Bakker<sup>2</sup>, Désirée van der Heijde<sup>2</sup>, Ulrich Weber<sup>3,4</sup>, Martin Rudwaleit<sup>5</sup>, Kay-Geert A Hermann<sup>6</sup>,

ÍNDICE

CRITERIOS ASAS

DAÑO  
ESTRUCTURAL

SECUENCIAS  
DIFUSIÓN

CONCLUSIÓN

In summary, new data were presented indicating that:

- For the SI joint, the current definition of a positive MRI (active sacroiliitis) performs satisfactorily for the classification of axial SpA according to the ASAS axial SpA criteria, and can be interpreted across many centres with substantial reader agreement.
- Evaluation of structural features, especially erosions, may enhance confidence in the classification of axial SpA emphasising the importance of simultaneous assessment of T1W and fat-suppressed sequences, and the contextual interpretation of MRI. However, the effect on classification of the addition of any structural damage feature to the definition of a positive SI joint MRI is not yet clear, in part due to variations in MRI acquisition protocol and advancing MRI technology that compounded the complexities of achieving consensus for definitions for each MRI structural damage lesion and the setting of thresholds for any defined lesion or combination of lesions.
- There is no consistent beneficial effect of adding features of SpA on spine MRI to the definition.

Following extensive discussion, the consensus opinion of the group was that 'The definition of a positive MRI should not be changed at this time. The utility of the structural damage changes of the SI joints and the addition of features on MRI of the spine for classification purposes is not yet clear and this continues to be an important research agenda'. The available data (not all data from some references were available at the time) were then presented and discussed at the annual assembly of ASAS on 17 January 2014. The meeting concluded with voting open to all members and a proposal to not change the existing definition was unanimously approved.

ÍNDICE

CRITERIOS ASAS

DAÑO  
ESTRUCTURAL

SECUENCIAS  
DIFUSIÓN

CONCLUSIÓN

**Box 1 Definition of a positive MRI (active sacroiliitis) for the classification of axial spondyloarthritis (SpA) according to the Assessment in SpondyloArthritis International Society (ASAS) axial SpA criteria**

Inflammation of the sacroiliac joints highly suggestive of SpA is required for the fulfilment of the imaging criterion 'active sacroiliitis on MRI' according to the ASAS classification criteria for axial SpA.

The requirements are listed below and guidelines for the application of the definition are provided in box 2.

REQUIRED MRI evidence of bone marrow inflammation must be present and the features required for the definition of active sacroiliitis on MRI are:

- 1. Bone marrow oedema (BMO) on a T2-weighted sequence sensitive for free water (such as short tau inversion recovery (STIR) or T2FS) or bone marrow contrast enhancement on a T1-weighted sequence (such as T1FS post-Gd).
- 2. Inflammation must be clearly present and located in a typical anatomical area (subchondral bone).
- 3. MRI appearance must be highly suggestive of SpA.

NOT REQUIRED Other findings related to sacroiliitis may be observed on MRI but are not required to fulfil the imaging criterion 'active sacroiliitis on MRI':

- The sole presence of other inflammatory lesions such as synovitis, enthesitis or capsulitis without concomitant BMO is not sufficient for the definition of 'active sacroiliitis on MRI'.
- In the absence of MRI signs of BMO, the presence of structural lesions such as fat metaplasia, sclerosis, erosion or ankylosis does not meet the definition of 'active sacroiliitis on MRI'.

ÍNDICE

CRITERIOS ASAS

DAÑO  
ESTRUCTURAL

SECUENCIAS  
DIFUSIÓN

CONCLUSIÓN

### Box 2 Guidelines for the application of the definition of a positive MRI (active sacroiliitis) for the classification of axial spondyloarthritis (SpA)

MRI interpretation:

- Bone marrow oedema (BMO) representing an inflammatory lesion that meets the above criterion will usually be easily seen on at least two consecutive slices of an MRI scan. Detection of inflammation on a single slice may be sufficient for the criterion 'highly suggestive of SpA' if there is more than one inflammatory lesion present. However, it is rare for an MRI scan of the sacroiliac joints with definite evidence of active sacroiliitis to demonstrate lesions on only a single image, and caution should be exercised in the interpretation of small lesions.
- It is essential that the reader of the MRI scan simultaneously review sequences designed to identify inflammation and sequences that focus on depiction of structural damage.
- If an inflammatory bone marrow lesion appears to be present but it is hard to determine whether the lesion meets the criterion 'highly suggestive of SpA', then the decision may be influenced by the presence of concomitant structural damage, especially erosion, and/or other signs of inflammation, which in themselves do not suffice to meet the criterion.

Context:

- Evaluation of an MRI scan should be performed objectively. However, MRI findings are non-specific and the determination of the importance of the observations should never be made in isolation of the clinical context as demographic, clinical and laboratory information may outweigh the importance of the MRI findings.
- The definition and guidelines are primarily for the classification of patients with SpA and will not be suitable for use in some clinical situations.



ÍNDICE

CRITERIOS ASAS

DAÑO ESTRUCTURAL

SECUENCIAS DIFUSIÓN

CONCLUSIÓN

### Box 2 Guidelines for the application of the definition of a positive MRI (active sacroiliitis) for the classification of axial spondyloarthritis (SpA)

MRI interpretation:

- Bone marrow oedema (BMO) representing an inflammatory lesion that meets the above criterion will usually be easily seen on at least two consecutive slices of an MRI scan. Detection of inflammation on a single slice may be sufficient for the criterion 'highly suggestive of SpA' if there is more than one inflammatory lesion present. However, it is rare for an MRI scan of the sacroiliac joints with definite evidence of active sacroiliitis to demonstrate lesions on only a single image, and caution should be exercised in the interpretation of small lesions.
- It is essential that the reader of the MRI scan simultaneously review sequences designed to identify inflammation and sequences that focus on depiction of structural damage.
- If an inflammatory bone marrow lesion appears to be present but it is hard to determine whether the lesion meets the criterion 'highly suggestive of SpA', then the decision may be influenced by the presence of concomitant structural damage, especially erosion, and/or other signs of inflammation, which in themselves do not suffice to meet the criterion.

Context:

- Evaluation of an MRI scan should be performed objectively. However, MRI findings are non-specific and the determination of the importance of the observations should never be made in isolation of the clinical context as demographic, clinical and laboratory information may outweigh the importance of the MRI findings.
- The definition and guidelines are primarily for the classification of patients with SpA and will not be suitable for use in some clinical situations.

ÍNDICE

CRITERIOS ASAS

DAÑO  
ESTRUCTURAL

SECUENCIAS  
DIFUSIÓN

CONCLUSIÓN

### Box 2 Guidelines for the application of the definition of a positive MRI (active sacroiliitis) for the classification of axial spondyloarthritis (SpA)

MRI interpretation:

- Bone marrow oedema (BMO) representing an inflammatory lesion that meets the above criterion will usually be easily seen on at least two consecutive slices of an MRI scan. Detection of inflammation on a single slice may be sufficient for the criterion 'highly suggestive of SpA' if there is more than one inflammatory lesion present. However, it is rare for an MRI scan of the sacroiliac joints with definite evidence of active sacroiliitis to demonstrate lesions on only a single image, and caution should be exercised in the interpretation of small lesions.
- It is essential that the reader of the MRI scan simultaneously review sequences designed to identify inflammation and sequences that focus on depiction of structural damage.
- If an inflammatory bone marrow lesion appears to be present but it is hard to determine whether the lesion meets the criterion 'highly suggestive of SpA', then the decision may be influenced by the presence of concomitant structural damage, especially erosion, and/or other signs of inflammation, which in themselves do not suffice to meet the criterion.

Context:

- Evaluation of an MRI scan should be performed objectively. However, MRI findings are non-specific and the determination of the importance of the observations should never be made in isolation of the clinical context as demographic, clinical and laboratory information may outweigh the importance of the MRI findings.
- The definition and guidelines are primarily for the classification of patients with SpA and will not be suitable for use in some clinical situations.

# Lesiones estructurales SI (Canada–Denmark MRI Working Group)

- **Depósito de m.ósea grasa (*Fat metaplasia*):** aumento de la señal subcondral o periarticular en T1; el tejido de referencia es la porción central (región interforaminal) del sacro.

ÍNDICE

CRITERIOS ASAS

DAÑO  
ESTRUCTURAL

SECUENCIAS  
DIFUSIÓN

CONCLUSIÓN

- **Erosión:** pérdida de grosor completo del margen, de baja señal, de la cortical articular ilíaca o sacra, *en la localización esperada*, con una zona de pérdida de la señal normal alta en T1 del hueso subcondral.
- **Relleno (*Backfill*):** pérdida completa de la cortical articular ilíaca o sacra, *en la localización esperada*, con aumento de la señal en T1, que se delimita claramente de la médula ósea normal, por baja señal irregular que refleja esclerosis.
- **Anquilosis:** señal de médula ósea en T1 extendiéndose entre las carillas articulares sacra e ilíaca.

# Erosiones

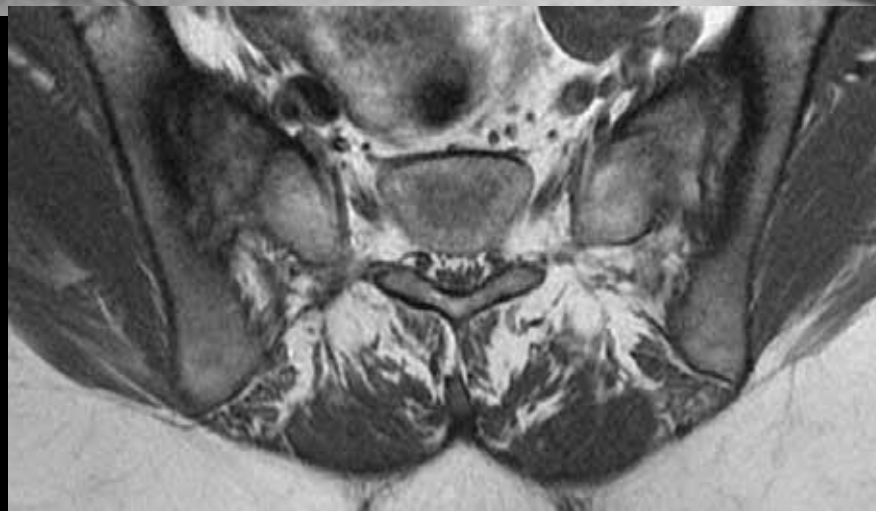
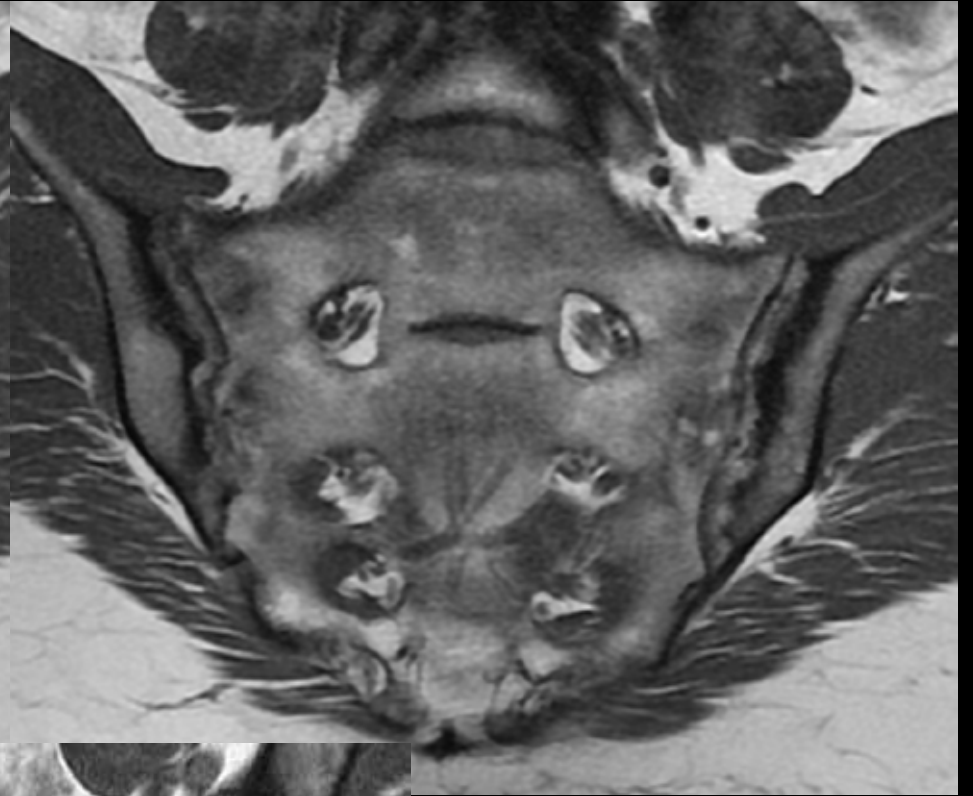
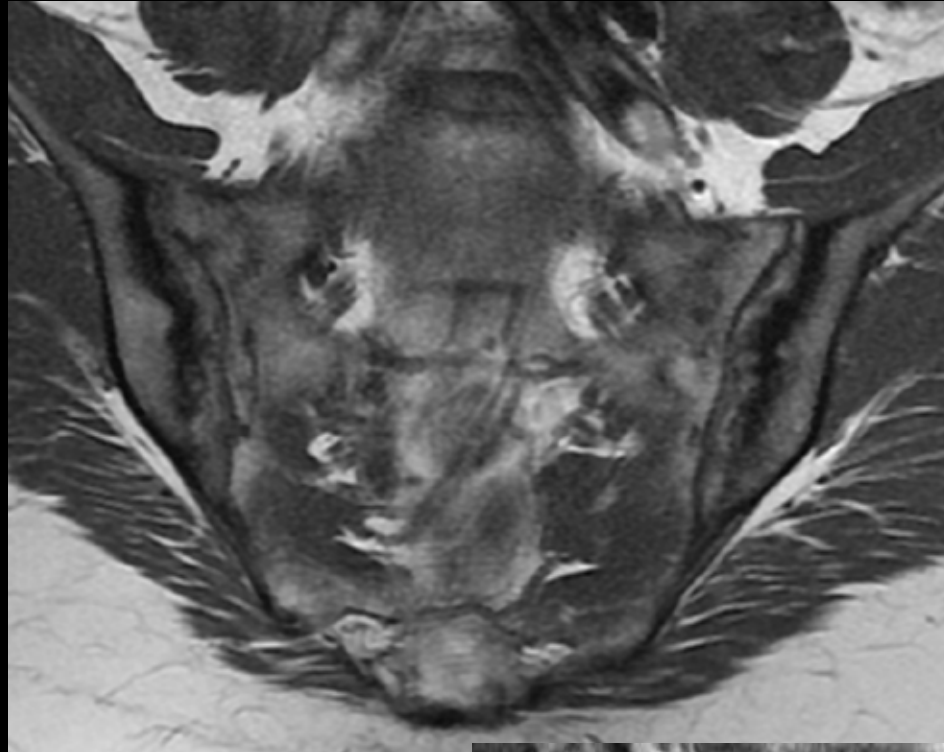
ÍNDICE

CRITERIOS ASAS

DAÑO  
ESTRUCTURAL

SECUENCIAS  
DIFUSIÓN

CONCLUSIÓN



ÍNDICE

CRITERIOS ASAS

DAÑO  
ESTRUCTURALSECUENCIAS  
DIFUSIÓNWHOLE  
BODY MRI

- An alternate definition of a positive MRI result, termed the MORPHO proposal, which defines SpA as being present on MRI if any of the following 3 criteria are met:
  - 1) bone marrow edema **in at least 2 SI joint quadrants** in the same slice or a single SI joint quadrant in 2 consecutive slices (according to the ASAS definition);
  - 2) **erosion** in at least 2 SI joint quadrants in the same slice or a single SI joint quadrant in 2 consecutive slices; and
  - 3) bone marrow edema and erosion in any SI joint quadrant though not necessarily in the same quadrant.

**Table 4.** Diagnostic utility of MRI by global assessment of all scans compared with the ASAS and MORPHO definitions of a positive MRI in patients with IBP\*

	Reader 1	Reader 2	Reader 3	Reader 4	Reader 5	Any 2 readers
Diagnosis by overall assessment						
Sensitivity	0.48	0.52	0.52	0.52	0.52	0.52
Specificity	0.98	0.97	0.94	0.99	0.99	0.95
Positive LR	20.0	14.8	8.8	43.4	43.3	9.8
Negative LR	0.5	0.5	0.5	0.5	0.5	0.5
Diagnosis by ASAS proposal						
Sensitivity	0.52	0.59	0.67	0.56	0.67	0.67
Specificity	0.93	0.92	0.85	0.94	0.89	0.88
Positive LR	7.3	7.3	4.5	8.8	6.0	5.7
Negative LR	0.5	0.4	0.4	0.5	0.4	0.4
Diagnosis by MORPHO proposal						
Sensitivity	0.74	0.63	0.78	0.70	0.74	0.81
Specificity	0.86	0.91	0.85	0.92	0.89	0.88
Positive LR	5.3	7.0	5.2	8.8	6.7	6.9
Negative LR	0.3	0.3	0.3	0.3	0.3	0.2

\* The Assessment of SpondyloArthritis international Society (ASAS) proposal for a positive magnetic resonance image (MRI) is  $\geq 2$  bone marrow edema (BME) lesions in 2 distinct sacroiliac joint (SIJ) quadrants on the same slice *or*  $\geq 1$  BME lesion extending across 2 SIJ quadrants *or*  $\geq 1$  BME lesion recorded on 2 consecutive slices in the same SIJ quadrant. The MORPHO proposal for a positive MRI is fulfillment of any of the following 3 criteria: BME according to the ASAS definition, erosion in  $\geq 2$  SIJ quadrants in the same slice *or* a single SIJ quadrant in 2 consecutive slices, *or* BME *and* erosion in any SIJ quadrant though not necessarily in the same quadrant. IBP = inflammatory back pain; LR = likelihood ratio.

- La introducción de la erosión en la definición de RM + condiciona un aumento de la Sensibilidad, del 67 al 81%, sin afectar la Especificidad, que no cambia del 88%.

ÍNDICE

CRITERIOS ASAS

DAÑO ESTRUCTURAL

SECUENCIAS DIFUSIÓN

WHOLE BODY MRI

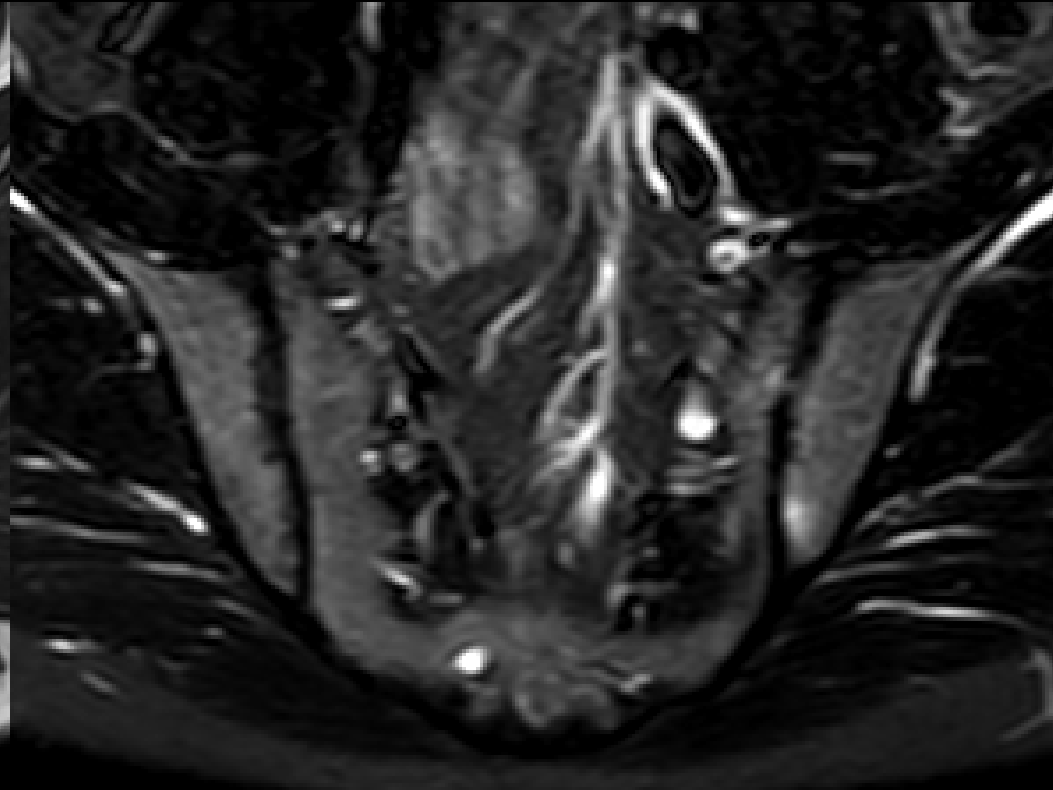
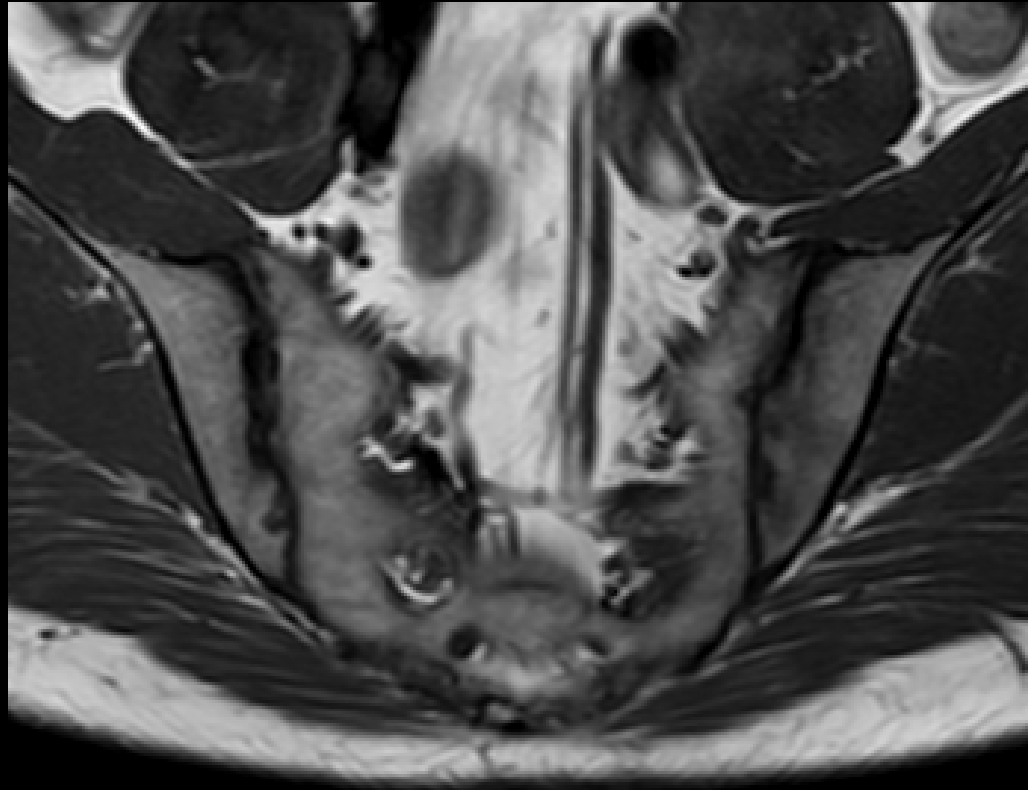
ÍNDICE

CRITERIOS ASAS

DAÑO  
ESTRUCTURAL

SECUENCIAS  
DIFUSIÓN

WHOLE  
BODY MRI



# Depósito MO grasa

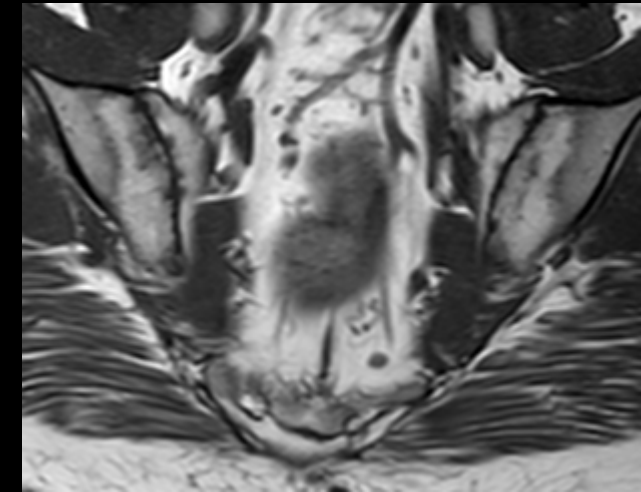
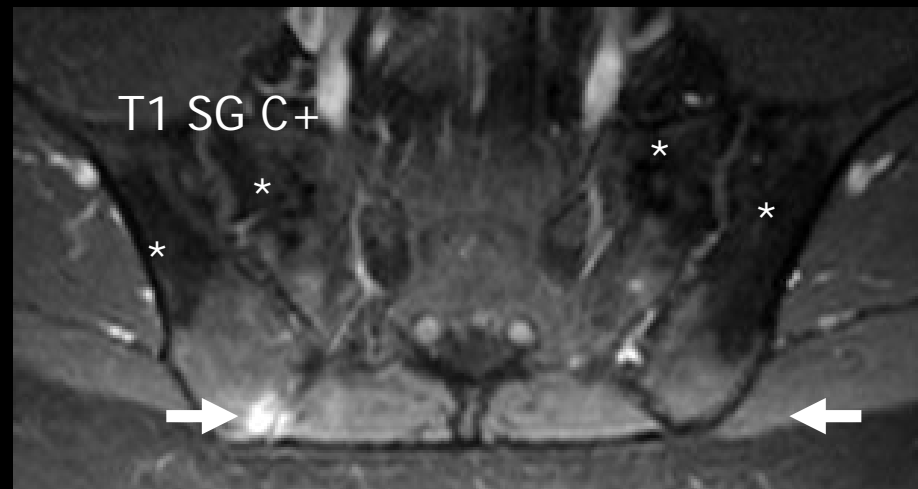
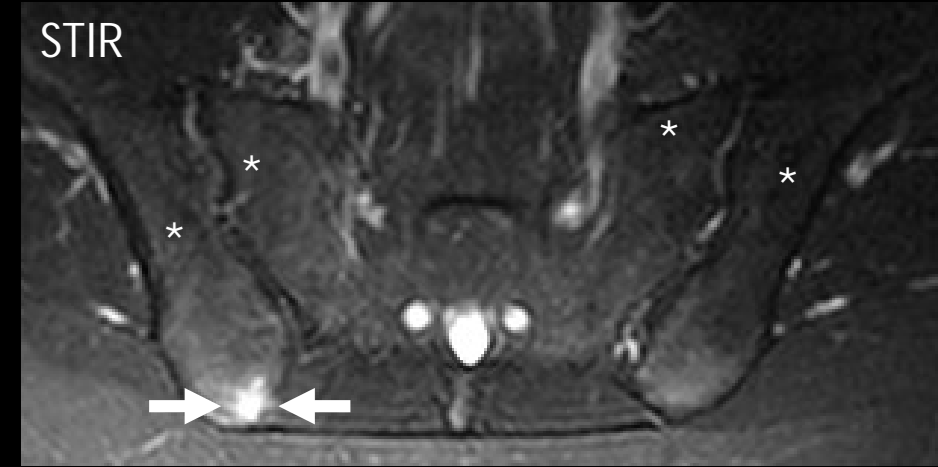
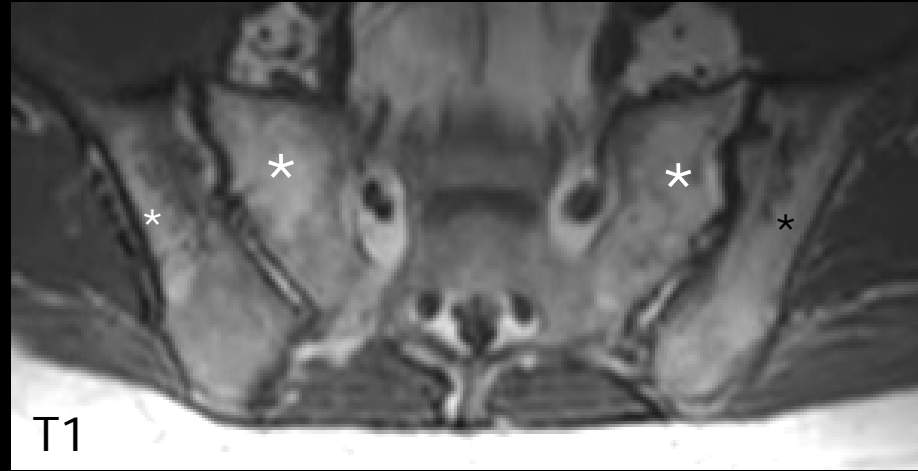
ÍNDICE

CRITERIOS ASAS

DAÑO ESTRUCTURAL

SECUENCIAS DIFUSIÓN

WHOLE BODY MRI



El valor diagnóstico del depósito de MO grasa no es bueno, porque solo proporciona información redundante condicionada por la presencia simultánea de edema y/o erosiones



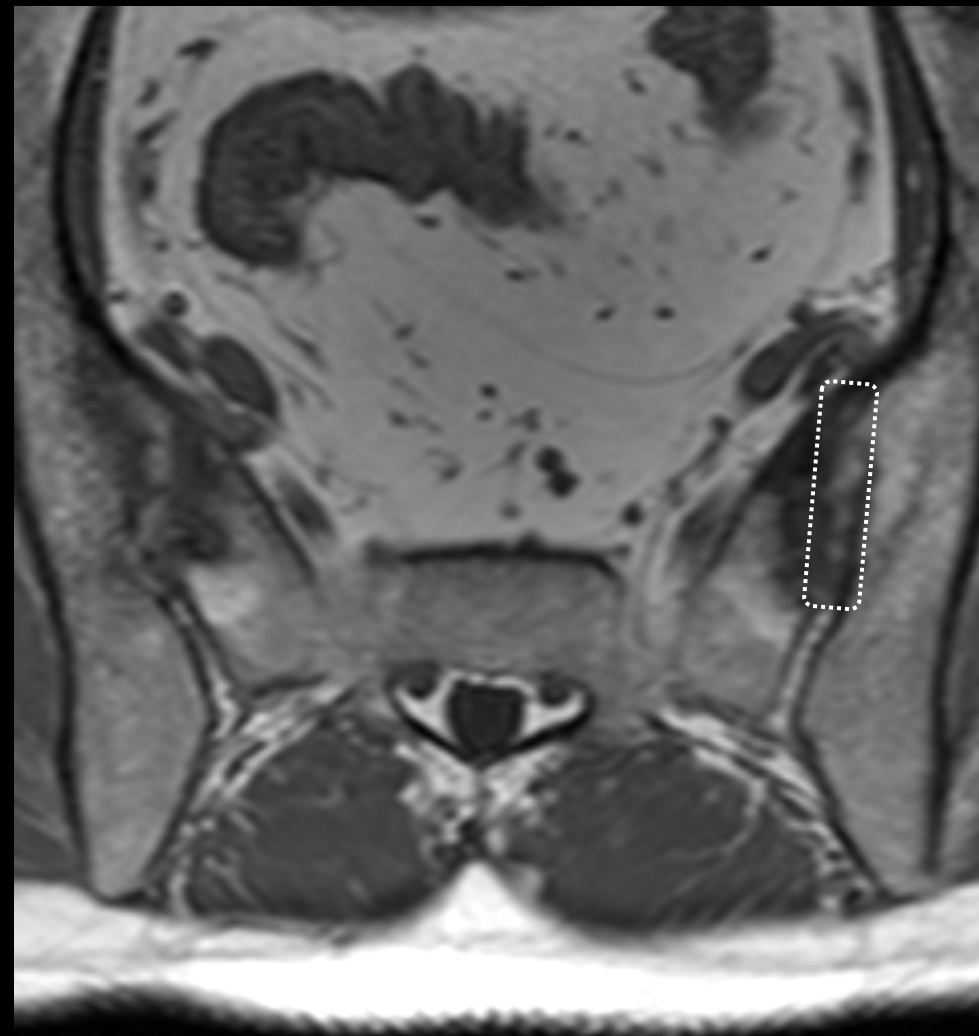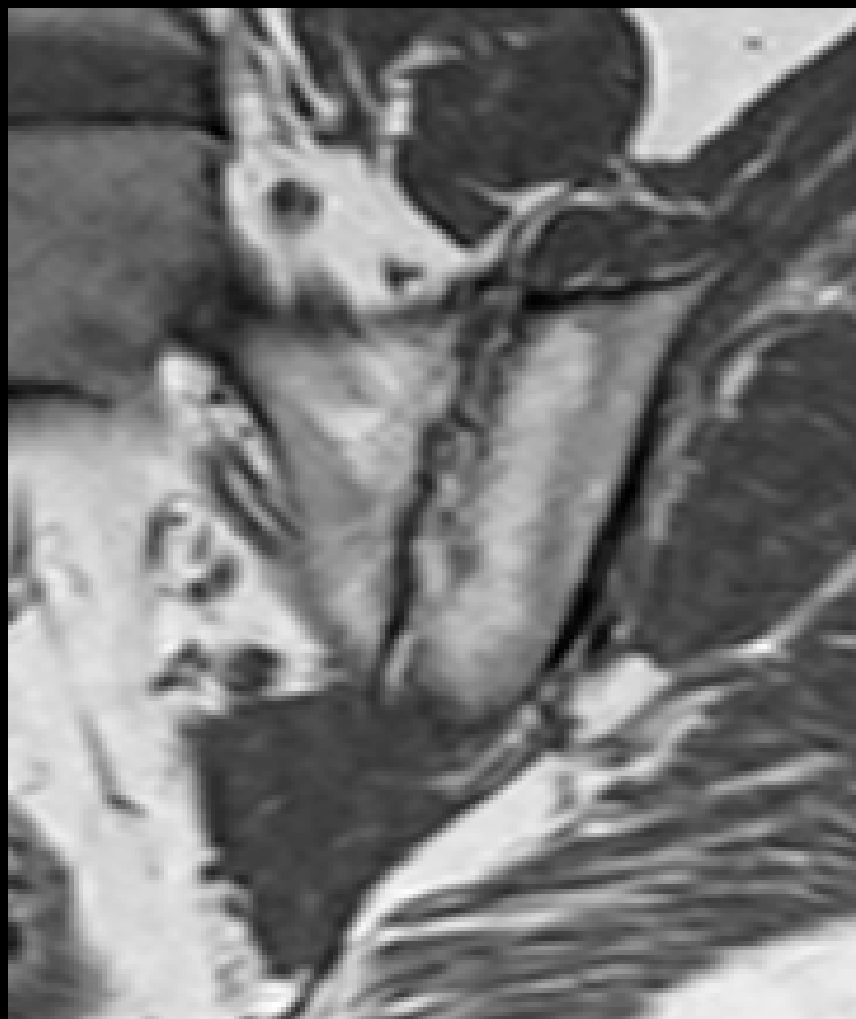
ÍNDICE

CRITERIOS ASAS

DAÑO  
ESTRUCTURAL

SECUENCIAS  
DIFUSIÓN

WHOLE  
BODY MRI



ÍNDICE

CRITERIOS ASAS

DAÑO  
ESTRUCTURAL

SECUENCIAS  
DIFUSIÓN

WHOLE  
BODY MRI

- 185 patients with nr-axSpA; MRI evaluated by two independent readers at baseline using the Spondyloarthritis Research Consortium of Canada (SPARCC) score.
- 128/183 (69.9%) patients had SIJ BME scores  $\geq 2$  and 55/183 (30.1%) had scores  $< 2$ .
- Frequencies of MRI structural lesions in patients with vs without SIJ BME were: erosions (45.3% vs 10.9%,  $P < 0.001$ ), backfill (20.3% vs 0%,  $P < 0.001$ ), fat metaplasia (10.9% vs 1.8%,  $P = 0.04$ ), and ankylosis (2.3% vs 1.8%,  $P = \text{ns}$ ).

ÍNDICE

CRITERIOS ASAS

DAÑO  
ESTRUCTURAL

SECUENCIAS  
DIFUSIÓN

WHOLE  
BODY MRI

*Arthritis Rheumatol.* 2014 Nov;66(11):2958-67. doi: 10.1002/art.38792.

## Fat metaplasia and backfill are key intermediaries in the development of sacroiliac joint ankylosis in patients with ankylosing spondylitis.

Maksymowych WP<sup>1</sup>, Wichuk S, Chiochanwisawakit P, Lambert RG, Pedersen SJ.

### Author information

### Abstract

**OBJECTIVE:** Fat metaplasia in bone marrow on T1-weighted magnetic resonance imaging (MRI) scans may develop after resolution of inflammation in patients with ankylosing spondylitis (AS) and may predict new bone formation in the spine. Similar tissue, termed backfill, may also fill areas of excavated bone in the sacroiliac (SI) joints and may reflect resolution of inflammation and tissue repair at sites of erosions. The purpose of this study was to test our hypothesis that SI joint ankylosis develops following repair of erosions and that tissue characterized by fat metaplasia is a key intermediary step in this pathway.

**METHODS:** We used the Spondyloarthritis Research Consortium of Canada (SPARCC) SI structural lesion score (SSS) method to assess fat metaplasia, erosions, backfill, and ankylosis on MRIs of the SI joints in 147 patients with AS monitored for 2 years. Univariate and multivariate regression analyses focused first on identifying significant MRI predictors of new backfill and fat metaplasia. We then assessed the role of backfill and fat metaplasia in the development of new ankylosis. All analyses were adjusted for demographic features, treatment, and baseline and 2-year change in SSS values for parameters of inflammation and MRI structural lesions.

**RESULTS:** Resolution of inflammation and reduction of erosions were each independently associated with the development of new backfill and fat metaplasia at 2 years on multivariate analyses. Multivariate regression analysis that included demographic features, baseline and 2-year change in parameters of inflammation and MRI structural lesion showed that reduction in erosions ( $P = 0.0005$ ) and increase in fat metaplasia ( $P = 0.002$ ) at 2 years was each independently associated with the development of new ankylosis.

**CONCLUSION:** Our data support a disease model whereby ankylosis develops following repair of erosions, and fat metaplasia and backfill are key intermediary steps in this pathway.

Copyright © 2014 by the American College of Rheumatology.

PMID: 25047851 [PubMed - indexed for MEDLINE]





## MRI of the sacroiliac joints in spondyloarthritis: the added value of intra-articular signal changes for a 'positive MRI'

Frederiek Laloo<sup>1</sup> · N. Herregods<sup>1</sup> · J. L. Jaremko<sup>2</sup> · K. Verstraete<sup>1</sup> · L. Jans<sup>1</sup>

Received: 19 April 2017 / Revised: 12 November 2017 / Accepted: 15 November 2017  
© ISS 2017

### Abstract

**Objective** To determine if intra-articular signal changes at the sacroiliac joint space on MRI have added diagnostic value for spondyloarthritis, when compared to bone marrow edema (BME).

**Materials and methods** A retrospective study was performed on the MRIs of sacroiliac joints of 363 patients, aged 16–45 years, clinically suspected of sacroiliitis. BME of the sacroiliac joints was correlated to intra-articular sacroiliac joint MR signal changes: high T1 signal, fluid signal, ankylosis and vacuum phenomenon (VP). These MRI findings were correlated with final clinical diagnosis. Sensitivity (SN), specificity (SP), likelihood ratios (LR), predictive values and post-test probabilities were calculated.

**Results** BME had SN of 68.9%, SP of 74.0% and LR+ of 2.6 for diagnosis of spondyloarthritis. BME in absence of intra-articular signal changes had a lower SN and LR+ for spondyloarthritis (SN = 20.5%, LR+ 1.4). Concomitant BME and high T1 signal (SP = 97.2%, LR + = 10.5), BME and fluid signal (SP = 98.6%, LR + = 10.3) or BME and ankylosis (SP = 100%) had higher SP and LR+ for spondyloarthritis. Concomitant BME and VP had low LR+ for spondyloarthritis (SP = 91%, LR + = 0.9). When BME was absent, intra-articular signal changes were less prevalent, but remained highly specific for spondyloarthritis.

**Conclusion** Our results suggest that both periarticular and intra-articular MR signal of the sacroiliac joint should be examined to determine whether an MRI is 'positive' or 'not positive' for sacroiliitis associated with spondyloarthritis.

ÍNDICE

CRITERIOS ASAS

DAÑO  
ESTRUCTURAL

SECUENCIAS  
DIFUSIÓN

WHOLE  
BODY MRI

- ÍNDICE
- CRITERIOS ASAS
- DAÑO ESTRUCTURAL**
- SECUENCIAS DIFUSIÓN
- WHOLE BODY MRI

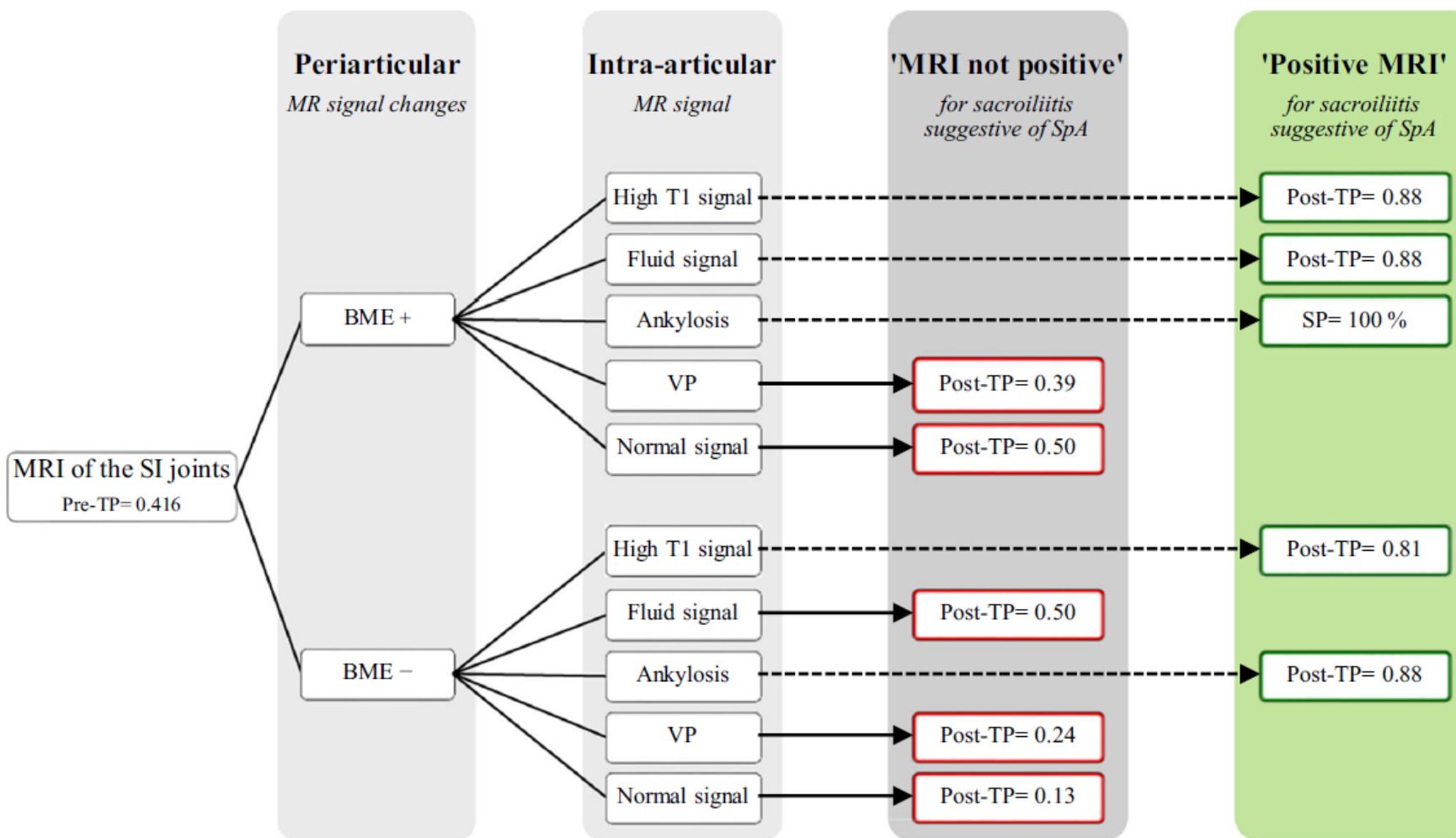


Fig. 10 Decision tree for clinical practice of assessing MR imaging of the SI joints for sacroiliitis suggestive of SpA, examining both periarticular and intra-articular MR signal (BME = bone marrow edema; VP = vacuum phenomenon; TP = test probability; SP = specificity)



- En 1827, Robert Brown describe el movimiento aleatorio de la partículas de polen suspendidas en agua. Albert Einstein publicó que el polen era movido por un movimiento de las moléculas de agua, denominado browniano en honor del primer investigador.

ÍNDICE

CRITERIOS ASAS

DAÑO  
ESTRUCTURAL

SECUENCIAS  
DIFUSIÓN

WHOLE  
BODY MRI

- **Difusión:** movimiento aleatorio (browniano) de las moléculas de agua que se encuentran a una  $t^a$  superior a  $-273^{\circ}\text{C}$ . Depende de propiedades del medio como la  $t^a$  o la viscosidad.
- En tejidos biológicos existen diferentes barreras, principalmente la membrana de las células, que limitan el movimiento libre (difusión) de las moléculas.
- La velocidad de la difusión es inversamente proporcional al  $n^{\circ}$  de células: tejido normal > lesiones benignas > tumores malignos.
- En la médula ósea normal hay poca celularidad, al igual que ocurre en las áreas de edema de la médula ósea, lo que nos permitía diferenciar la actividad inflamatoria

- Secuencia de RM que proporciona información cualitativa y cuantitativa sobre la difusión (movimiento browniano de las moléculas de agua) en los tejidos.
- La potenciación en difusión se mide por el valor  $b$  ( $\text{mm}^2/\text{seg}$ ): siempre se emplean más de dos valores, por lo que se obtienen dos series de cortes sobre la misma zona estudiada
- La cuantificación puede hacerse mediante el cálculo del ADC: *Apparent Diffusion Coefficient*, que representa la propiedad del tejido que se quiere medir mediante técnicas de difusión.

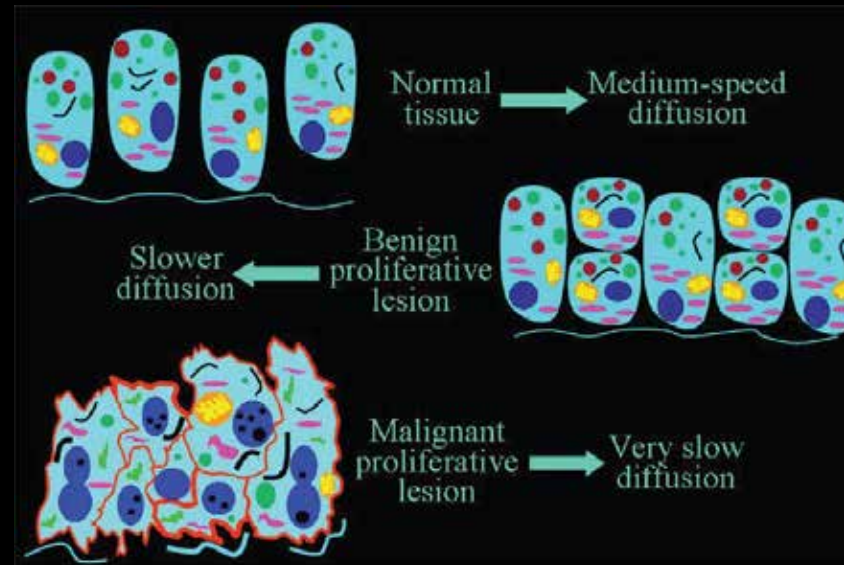
ÍNDICE

CRITERIOS ASAS

DAÑO ESTRUCTURAL

SECUENCIAS DIFUSIÓN

WHOLE BODY MRI





ÍNDICE

CRITERIOS ASAS

DAÑO  
ESTRUCTURAL

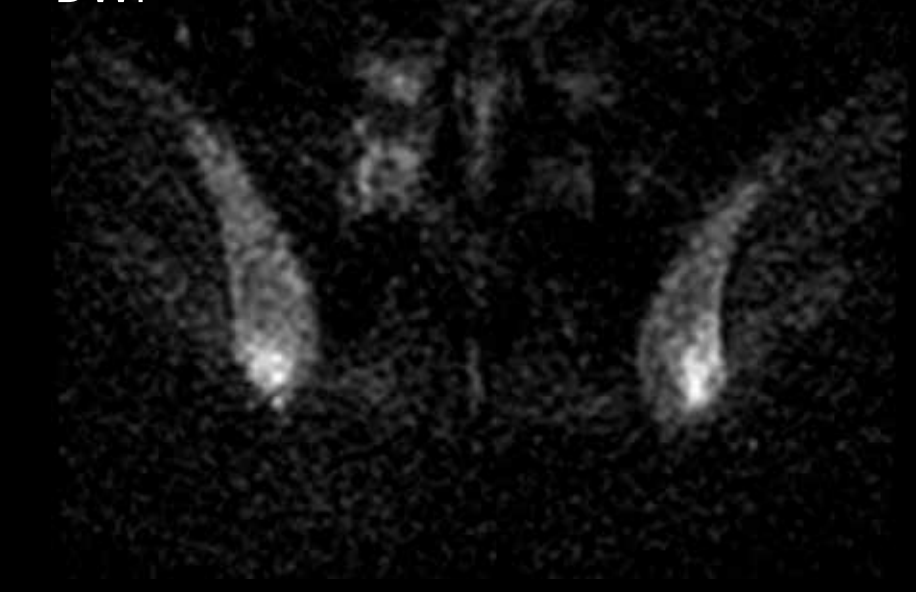
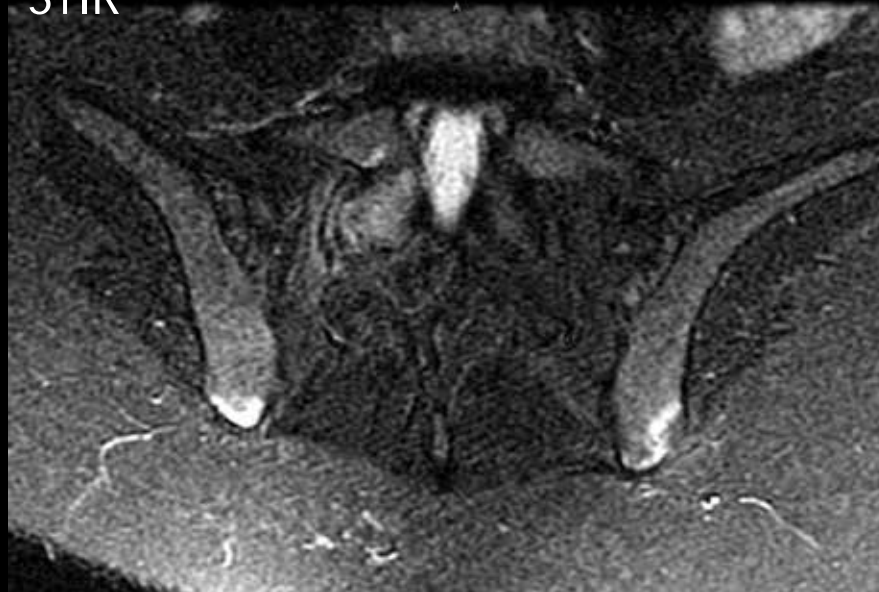
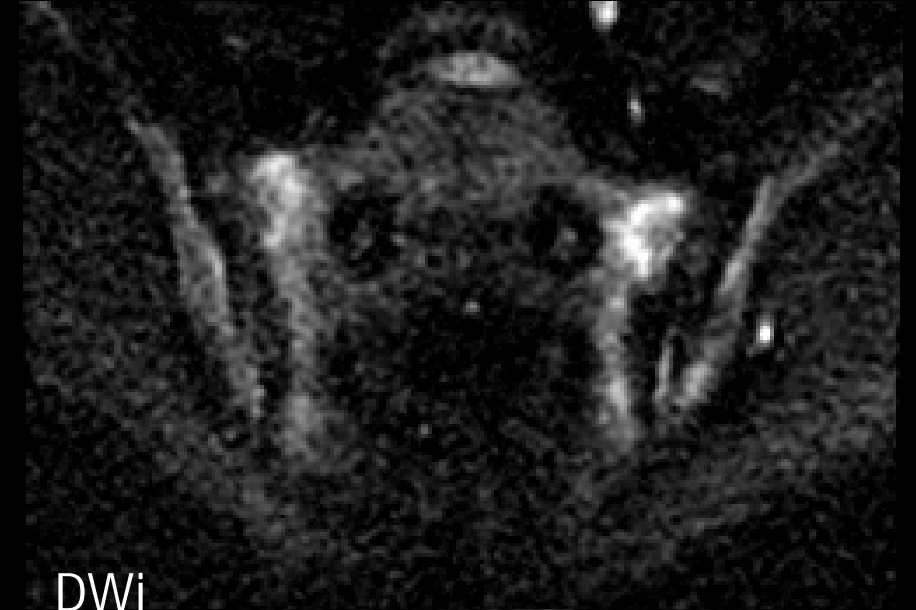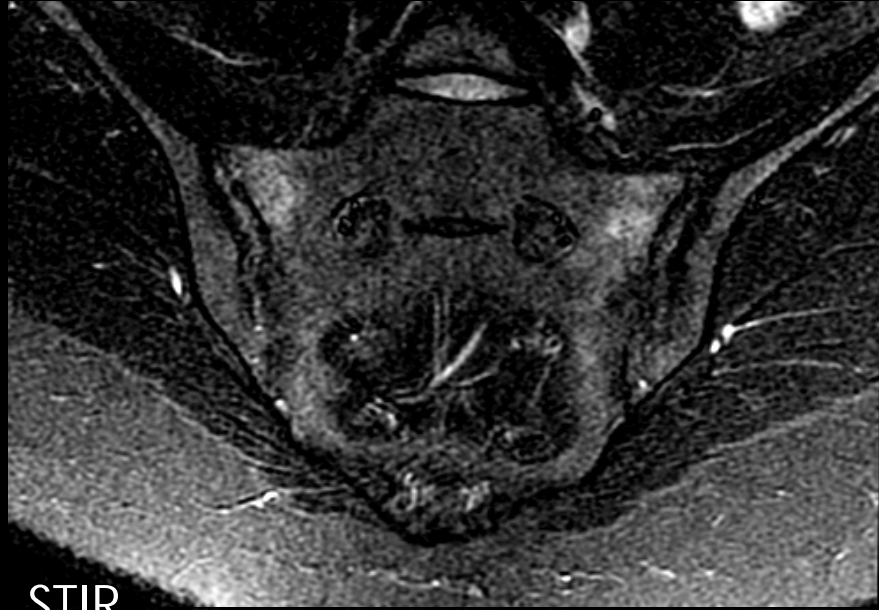
SECUENCIAS  
DIFUSIÓN

WHOLE  
BODY MRI

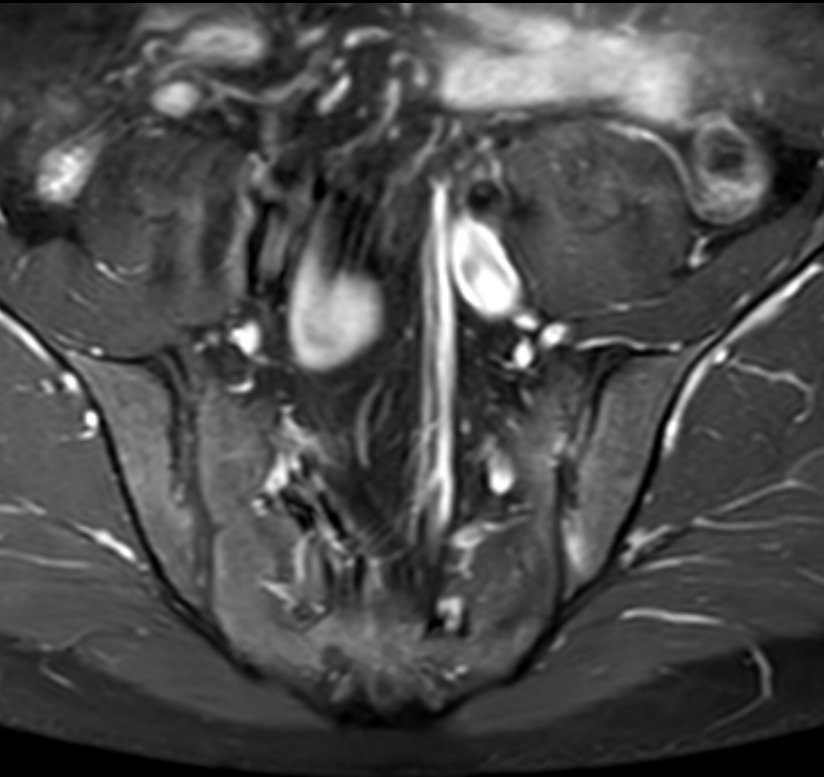
- La médula ósea normal tiene una baja celularidad , por lo tanto baja difusión, y valores bajos de ADC.
- El componente inflamatorio en la médula ósea propio de la osteítis (edema óseo en RM) restringe la difusión de las moléculas de agua tisulares, con valores de ADC mayores que los de la médula ósea normal.
- La variaciones en el grado de edema óseo se pueden cuantificar mediante el ADC



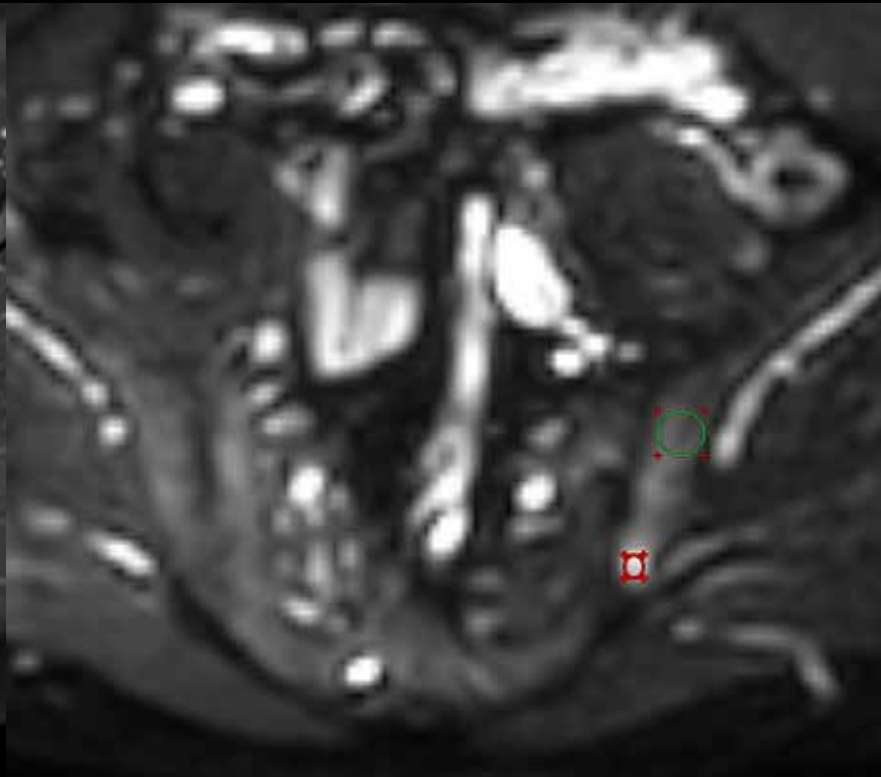
# Secuencias de Difusión



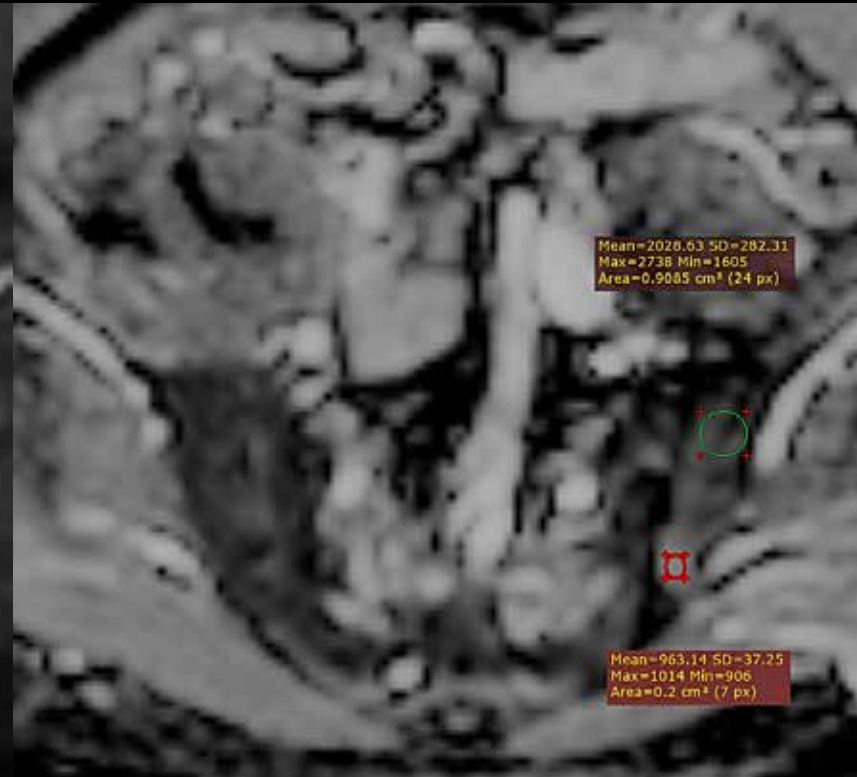
# Secuencias de Difusión



T1 SG Gd



Dwi  
( $b=1000 \text{ mm}^2/\text{s}$ )



ADC

ÍNDICE

CRITERIOS ASAS

DAÑO  
ESTRUCTURAL

SECUENCIAS  
DIFUSIÓN

WHOLE  
BODY MRI

- La difusión en RM es una técnica de RM relativamente novedosa, que permite identificar y cuantificar el edema óseo inflamatorio propio de las EspA, lo que puede ser útil en:
  - Útil como complemento de las secuencias T2 SG y/o STIR
  - Monitorización del tratamiento en EA: cuantificación del edema
  - Diferenciación del edema óseo subcondral discogénico (cambios de Modic tipo 1) de discitis aséptica (lesión de Andersson)

RESEARCH ARTICLE

## Diffusion-weighted imaging versus short tau inversion recovery sequence: Usefulness in detection of active sacroiliitis and early diagnosis of axial spondyloarthritis

Chiu Wai Shirley Chan<sup>1</sup>, Helen Hoi Lun Tsang<sup>1</sup>, Philip Hei Li<sup>1</sup>, Kam Ho Lee<sup>2</sup>, Chak Sing Lau<sup>1</sup>, Pui Yan Stella Wong<sup>3</sup>, Ho Yin Chung<sup>1\*</sup>

**1** Division of Rheumatology and Clinical Immunology, The University of Hong Kong, Hong Kong, China  
**2** Department of Radiology, Queen Mary Hospital, Hong Kong, Chir Kwan O Hospital, Hong Kong, China

\* [jameschunghoyn@gmail.com](mailto:jameschunghoyn@gmail.com)

### Conclusion

DWI and STIR have similar sensitivity in diagnosing axSpA in early disease. However, the use of DWI is limited by poorer reliability when compared with STIR.

## Does the Addition of DWI to Fluid-Sensitive Conventional MRI of the Sacroiliac Joints Improve the Diagnosis of Sacroiliitis?

Luis S. Beltran<sup>1</sup>  
Mohammad Samim  
Soterios Gyftopoulos  
Mary T. Bruno  
Catherine N. Petchprapa

AJR:210, June 2018

**CONCLUSION.** The addition of DWI to conventional MRI does not significantly improve overall diagnostic performance in terms of accuracy, sensitivity, or confidence in the detection of inflammatory sacroiliitis, but it does have increased specificity and interobserver agreement. ADC threshold values can be used as predictors of sacroiliitis but give no added advantage over MRI with DWI.

ÍNDICE

CRITERIOS ASAS

DAÑO ESTRUCTURAL

SECUENCIAS DIFUSIÓN

WHOLE BODY MRI

ÍNDICE

CRITERIOS ASAS

DAÑO  
ESTRUCTURAL

SECUENCIAS  
DIFUSIÓN

WHOLE  
BODY MRI

RHEUMATOLOGY

Rheumatology 2017;56:399–407

doi:10.1093/rheumatology/kew429

Advance Access publication 16 December 2016

Original article

## Diffusion-weighted imaging is a sensitive biomarker of response to biologic therapy in enthesitis-related arthritis

Timothy J. P. Bray<sup>1,2</sup>, Kanimozhi Vendhan<sup>1</sup>, Nicola Ambrose<sup>2</sup>, David Atkinson<sup>1</sup>, Shonit Punwani<sup>1</sup>, Corinne Fisher<sup>2</sup>, Debajit Sen<sup>2</sup>, Yiannis Ioannou<sup>2</sup> and Margaret A. Hall-Craggs<sup>1</sup>

# TAKE HOME MESSAGES

ÍNDICE

CRITERIOS ASAS

DAÑO  
ESTRUCTURAL

SECUENCIAS  
DIFUSIÓN

CONCLUSIÓN

- Magnetic resonance imaging (MRI) is essential in the process of diagnosis of axial spondyloarthritis (axSpA) in clinical practice.
- ASAS (Assessment of Spondyloarthritis international Society) classification criteria for axSpA are commonly used for diagnostic purposes, mainly in pre-radiographic stages.
- Bone edema is the only MRI finding considered in the definition of positive MRI of the sacroiliac joint.
- Diagnostic evaluation of SIJ MRI should not be based on BME alone, in particular if only minor lesions are present, but should adopt a contextual approach by taking into account structural lesions also, which appear early in the disease course and enhance specificity.

# TAKE HOME MESSAGES 2

- El Backill ("relleno" de erosiones) es una lesión estructural que representa un paso intermedio, junto con el depósito de m.ósea grasa, entre las erosiones y la anquilosis.
- La **difusión** en RM es una técnica de RM relativamente novedosa, que permite identificar y cuantificar el edema óseo inflamatorio propio de las EspA, lo que puede ser útil en:
  - Útil como complemento de las secuencias T2 SG y/o STIR
  - Monitorización del tratamiento en EA: cuantificación del edema
  - Diferenciación del edema óseo subcondral discogénico (cambios de Modic tipo 1) de discitis aséptica (lesión de Andersson)

ÍNDICE

CRITERIOS ASAS

DAÑO  
ESTRUCTURAL

SECUENCIAS  
DIFUSIÓN

CONCLUSIÓN

[jnarvaez@bellvitgehospital.cat](mailto:jnarvaez@bellvitgehospital.cat)

Gràcies!!

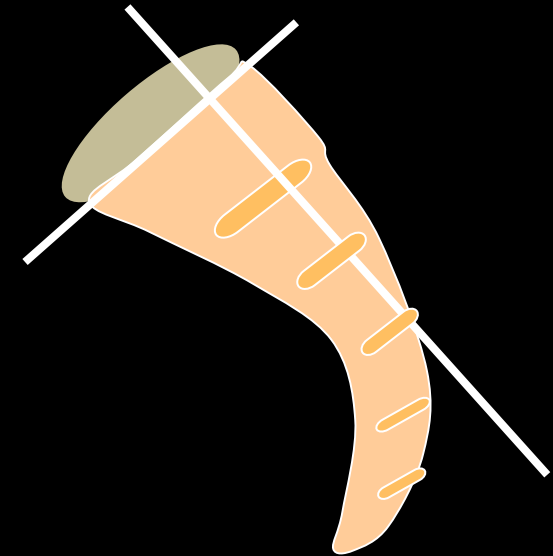




# TECHNICAL CONSIDERATIONS

## Sacroiliac Joints

- High field MR units are recommend
- **Imaging in two planes is required:** coronal oblique (oriented along the long axis of the sacral bone) and axial oblique plane.
- **Basic protocol:**
  - T1WI sequences -> to detect structural lesions
  - FS T2WI or STIR sequences -> to detect active inflammatory lesions.
- **Optional:**
  - **Use of IV Gadolinium** -> in questionable cases or when it is important to quantify inflammation
  - T1 FS of T2 gradient-echo sequences may be better to detect **erosions**



OUTLINE

ASAS CRITERIA

TECHNICAL  
CONSIDERATIONS

DIFFERENTIAL  
DIAGNOSIS

WRAPPING  
UP

# 2) Infectious Sacroiliitis

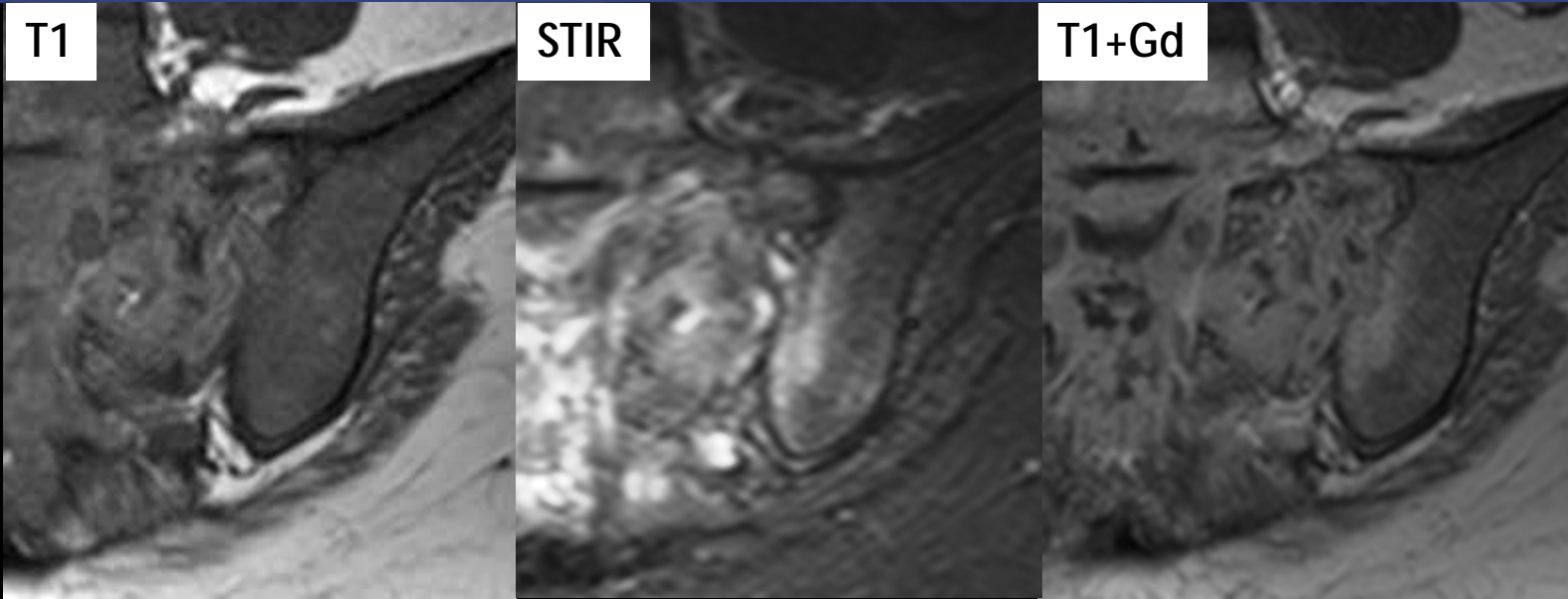
OUTLINE

ASAS CRITERIA

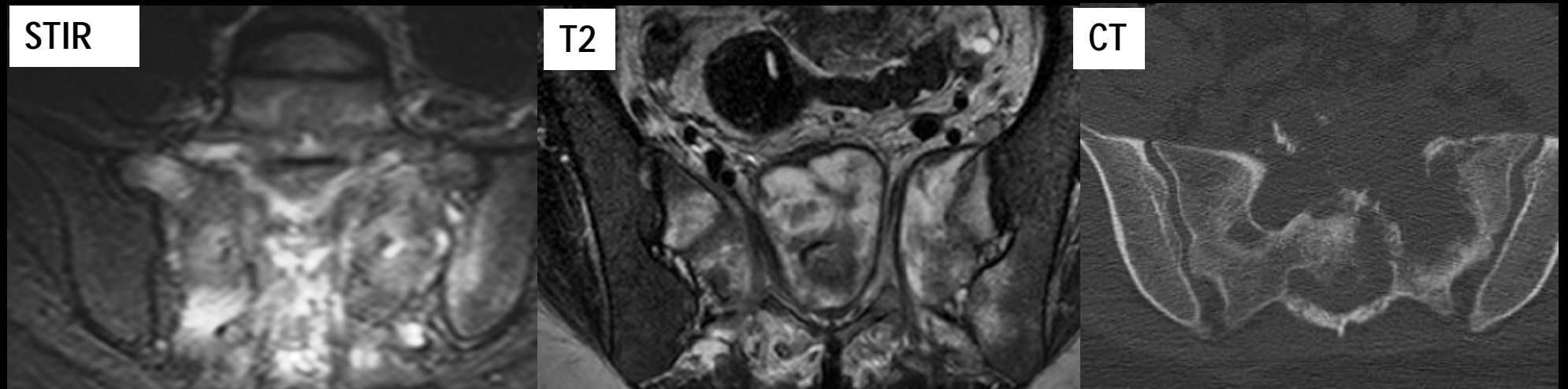
TECHNICAL  
CONSIDERATIONS

DIFFERENTIAL  
DIAGNOSIS

WRAPPING  
UP

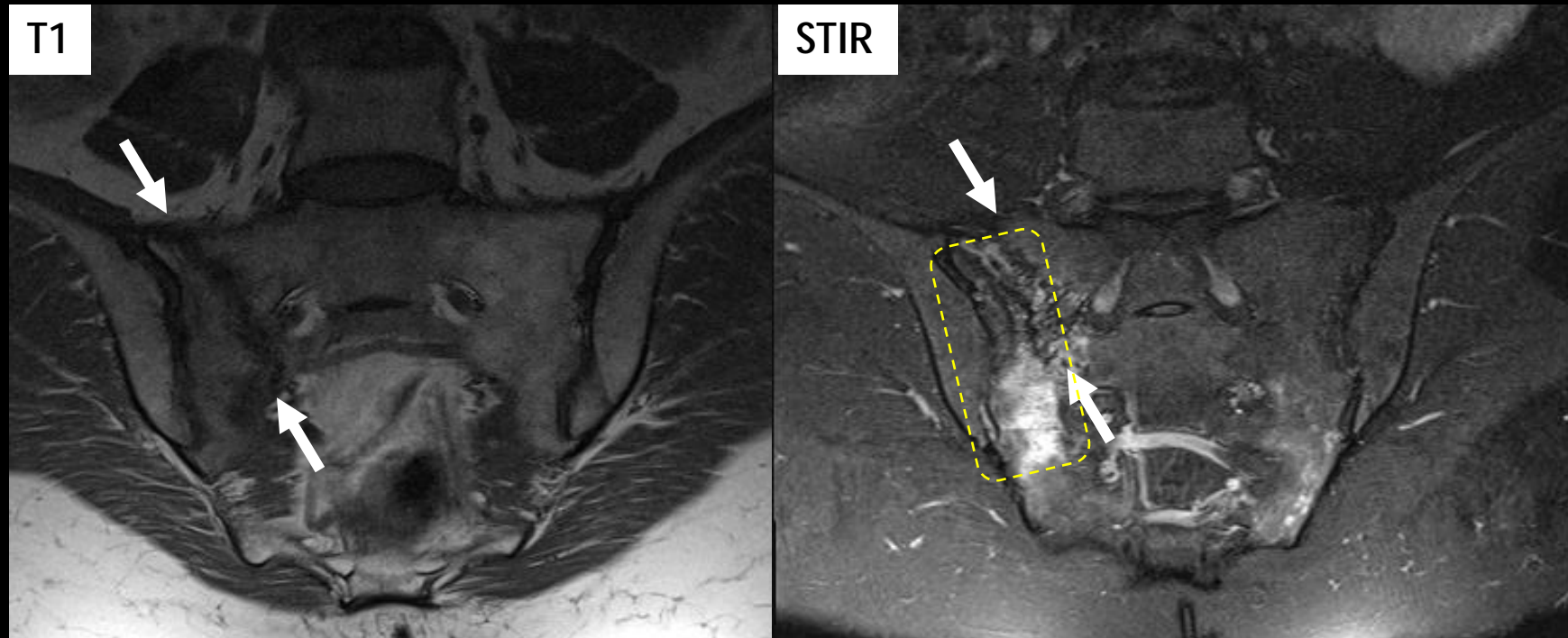


19 y.o. Female with long-standing low back pain



Tuberculous osteomyelitis, left sacroiliitis and L5-S1 dyskitis

# 4) Stress Fracture



69-year-old woman with mechanical low back pain...

**Insufficiency type Stress Fracture**



# Bellvitge

Hospital Universitari

## Greetings from Barcelona!

Comments are welcome,  
don't doubt to contact us at:

[jose\\_a\\_narvaez@hotmail.com](mailto:jose_a_narvaez@hotmail.com)



Acknowledgements to Dr. Pablo Naval  
for design presentation

