

# SOCIETAT CATALANA D'ANATOMIA PATOLÒGICA

## SESIÓN DE RESIDENTES (I) HEMATOPATOLOGÍA

**Yaroslav Zboromyrskyy**

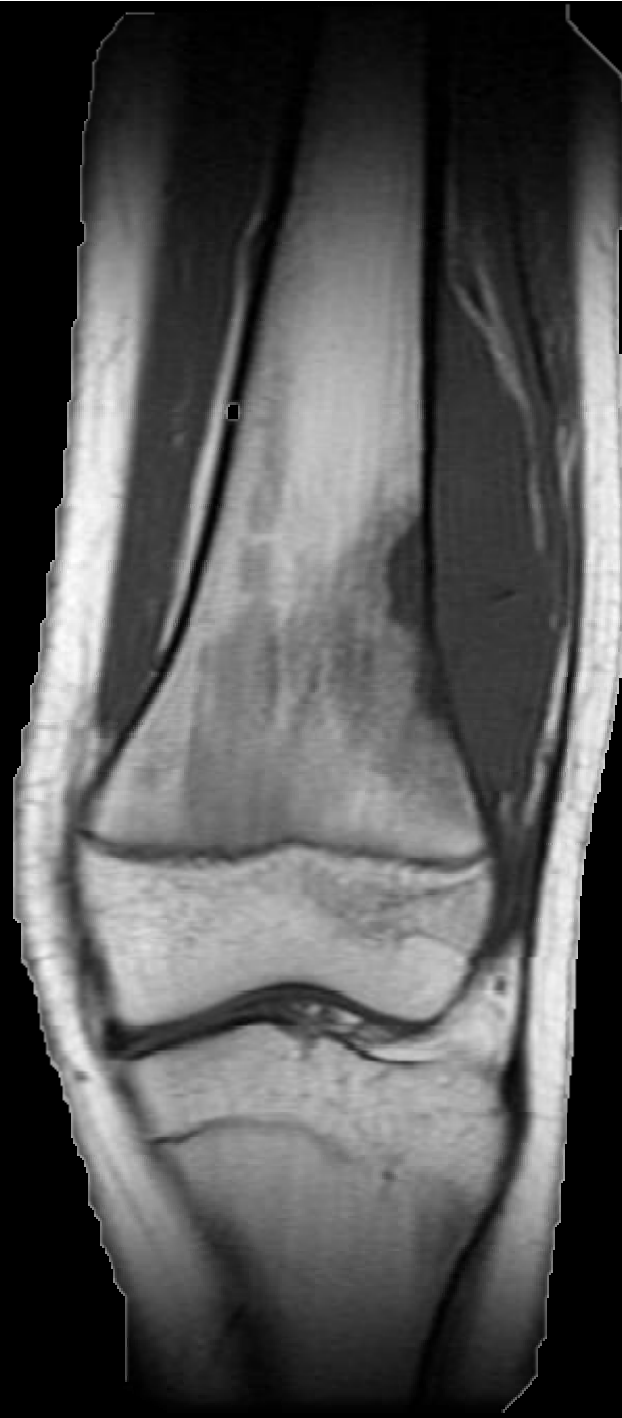

# Información Clínica

- Paciente, mujer de 15 años
- Sin antecedentes de interés
- Consulta por dolor en rodilla y cadera izquierdas que impiden la deambulaci3n
- P3rdida de 15 kg de peso en 3 meses
- Disfagia a alimentos s3lidos
- S3ndrome febril y sudoraci3n nocturna

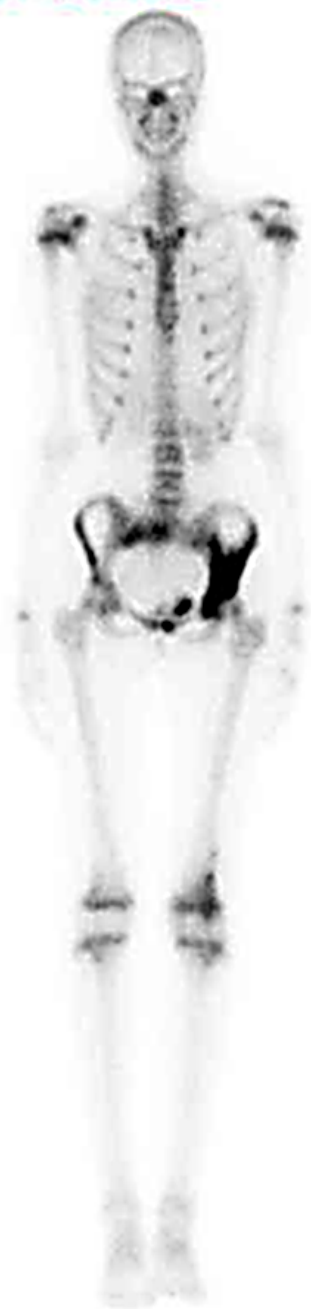# Exploración física

- Rodillas: clara asimetría, tumefacción en la izquierda con signos de derrame articular. Dolor y cojera con postura antiálgica
- Múltiples adenopatías laterocervicales y submandibulares

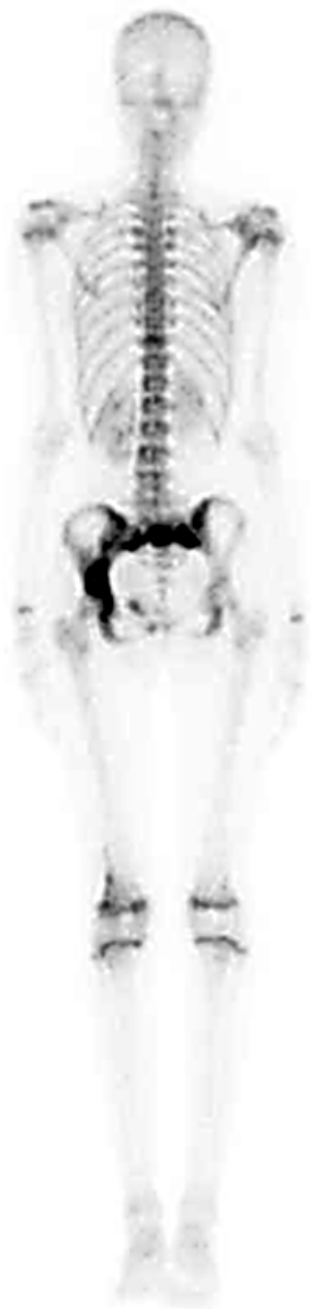



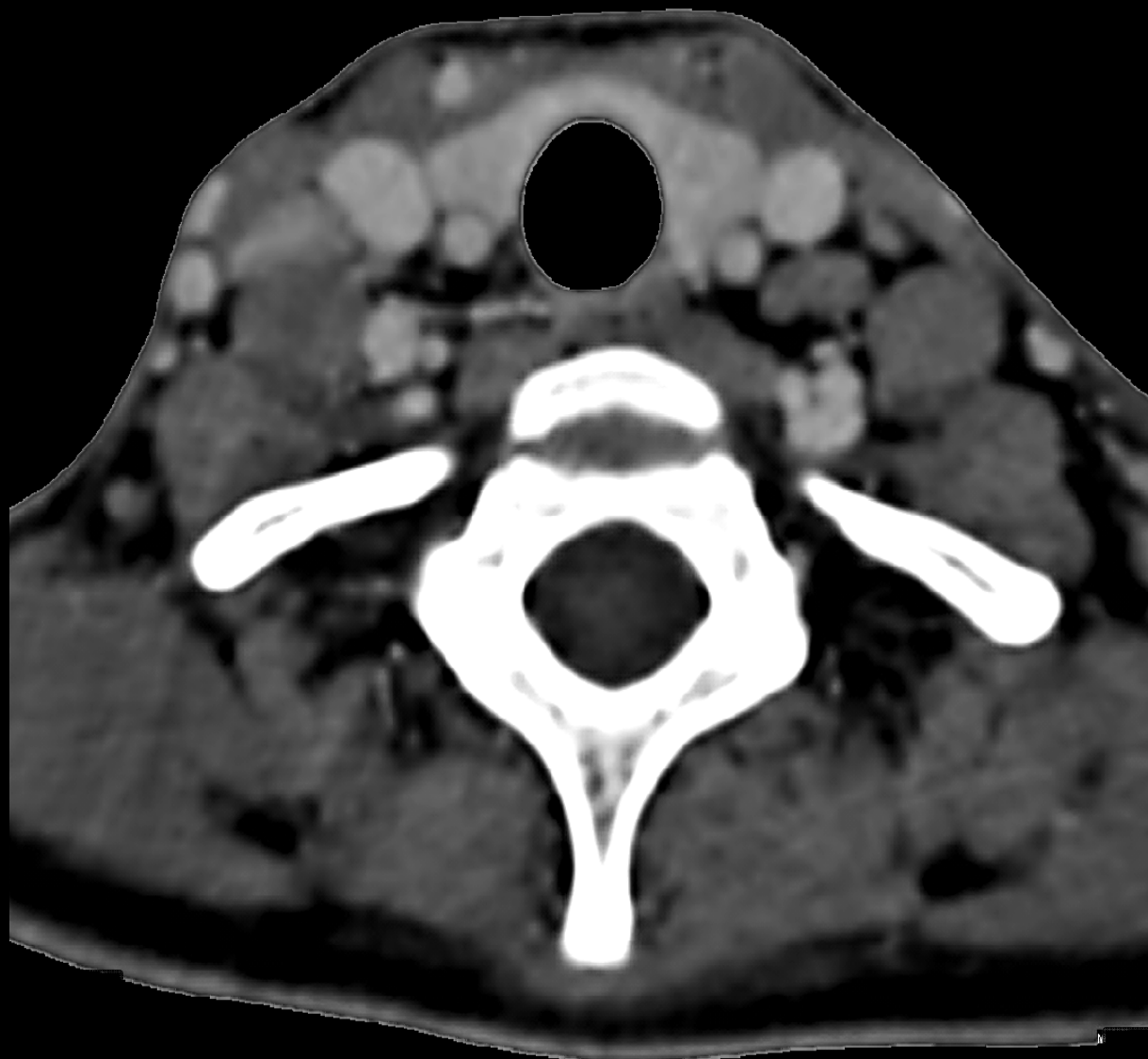**RASTREO OSEO**



**ANTERIOR**



**POSTERIOR**




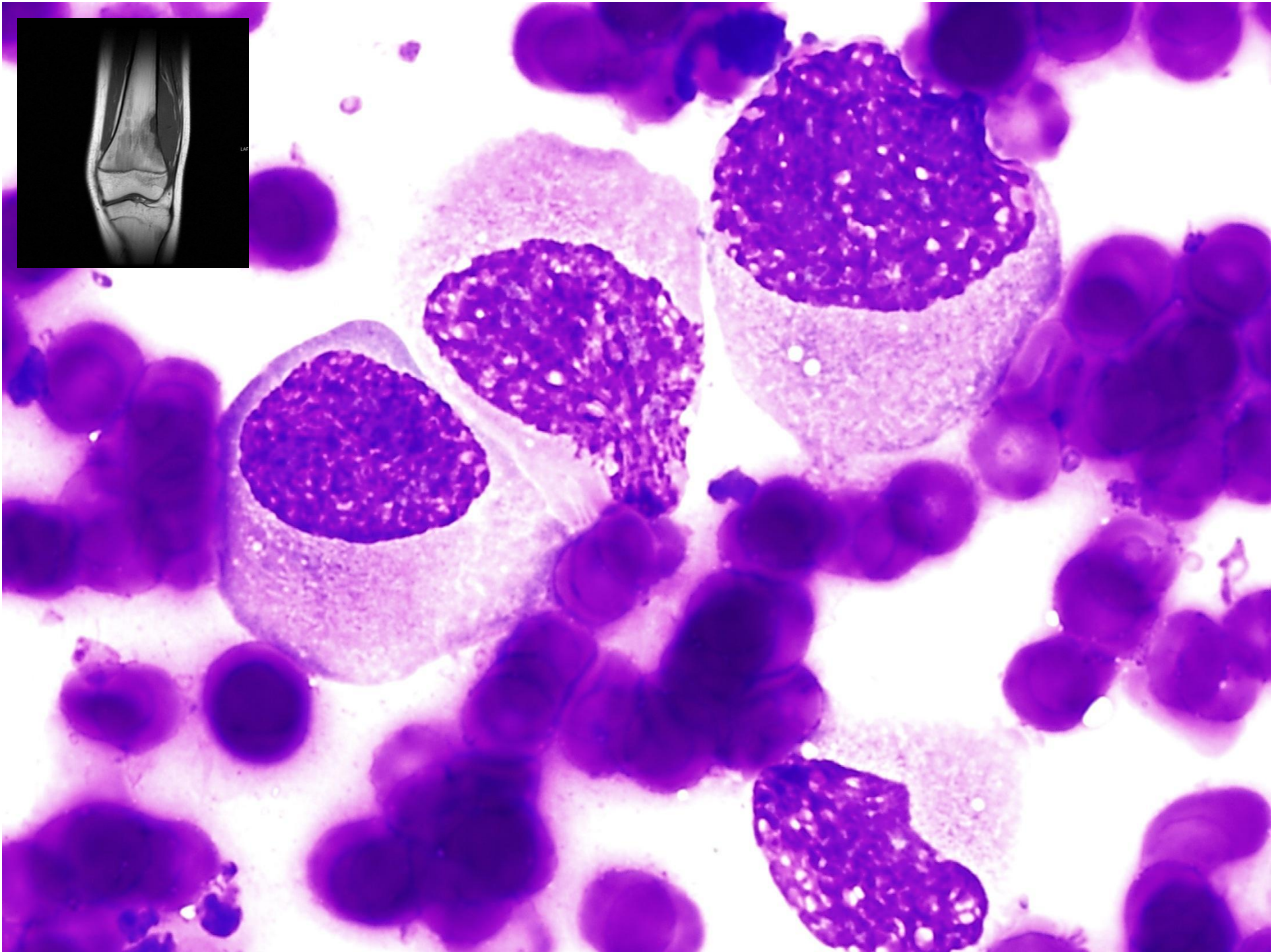
## **Gastroscoopia:**

- Tres lesiones sobreelevadas y dos lesiones ulceradas en la curvatura mayor de cuerpo estomago entre 15 y 25 mm de diámetro

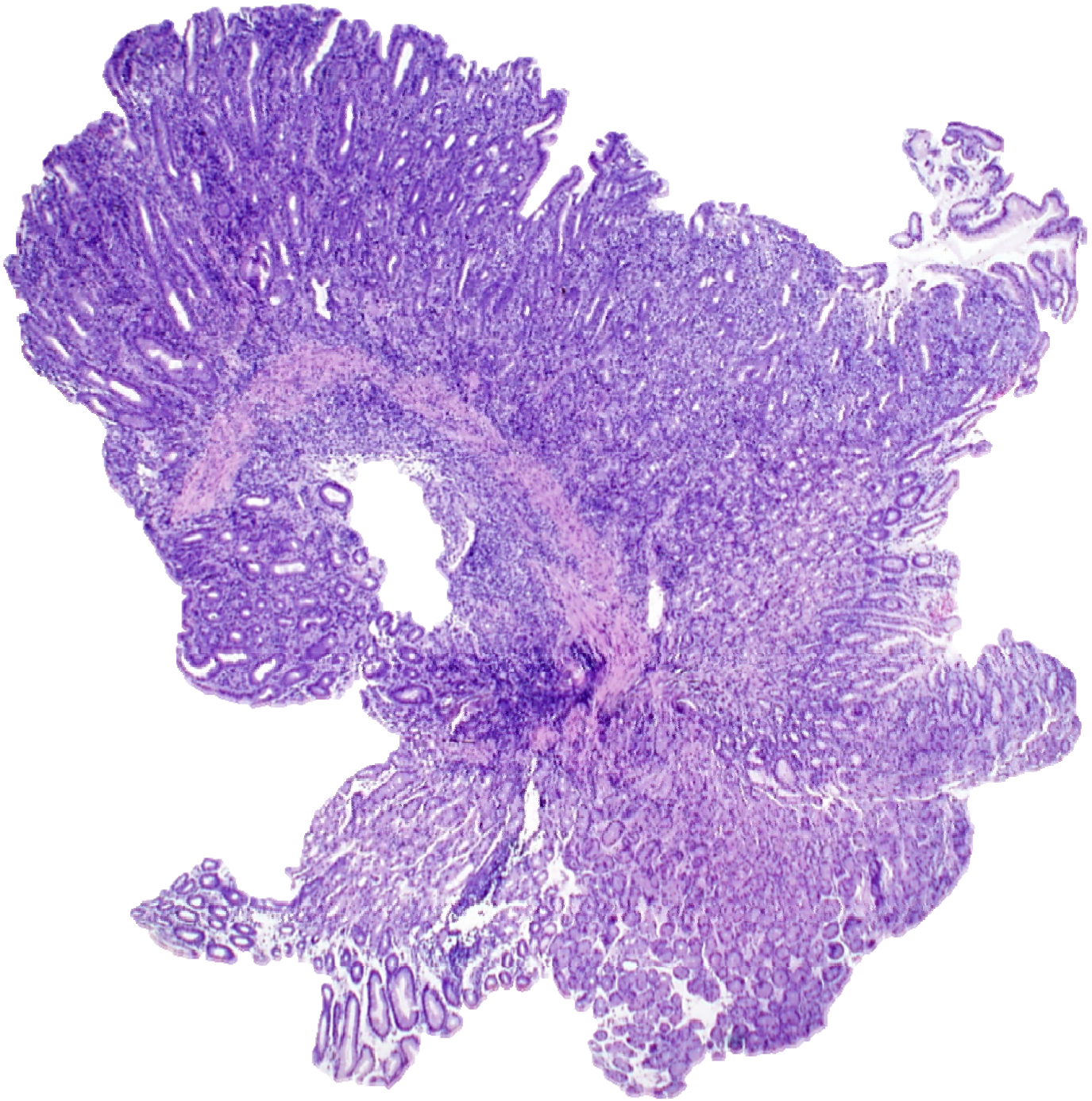


## **Se obtienen muestras de:**

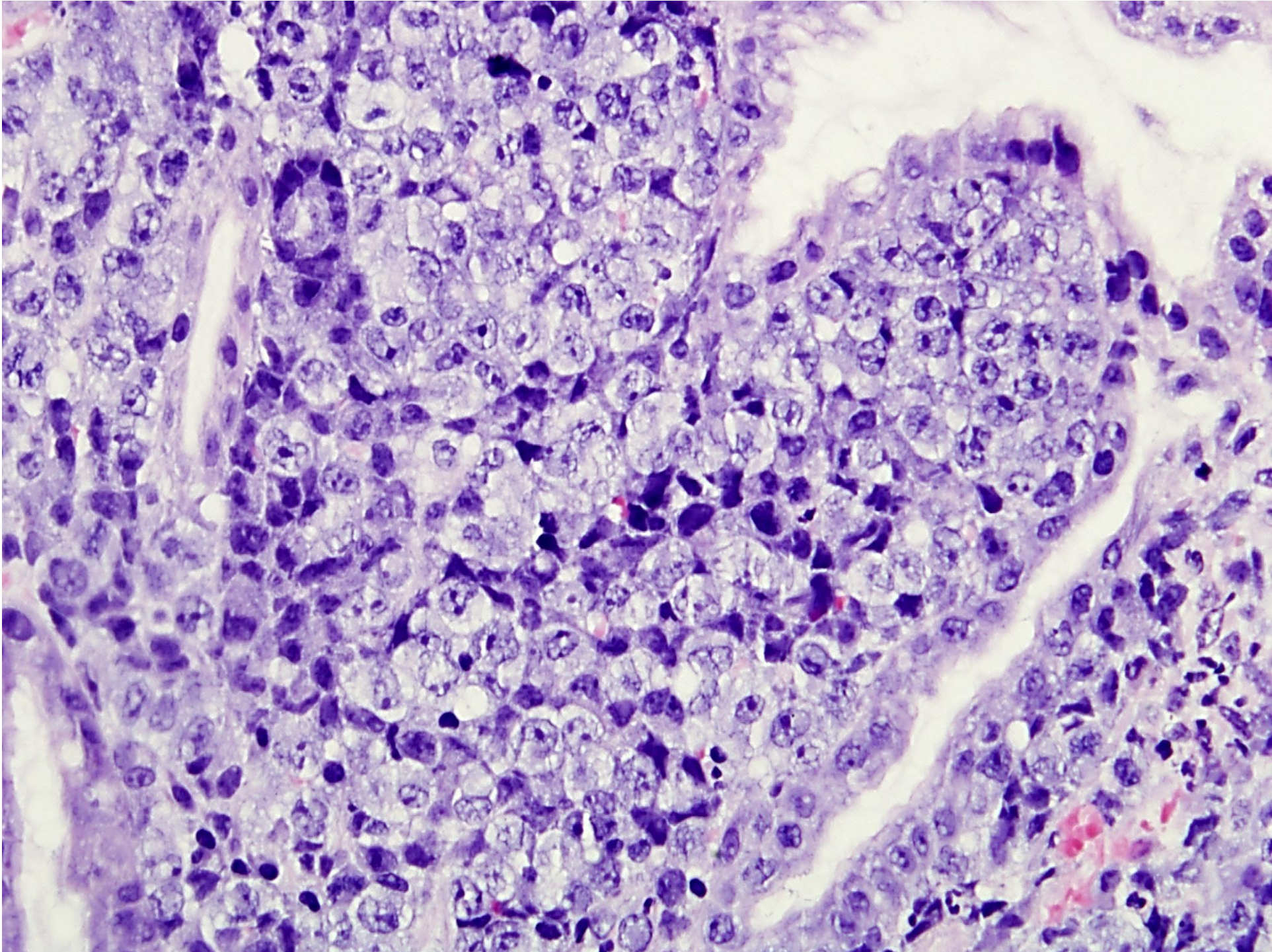
- Punción partes blandas rodilla
  - Biopsias mucosa gástrica
  - Exéresis adenopatía laterocervical
- 



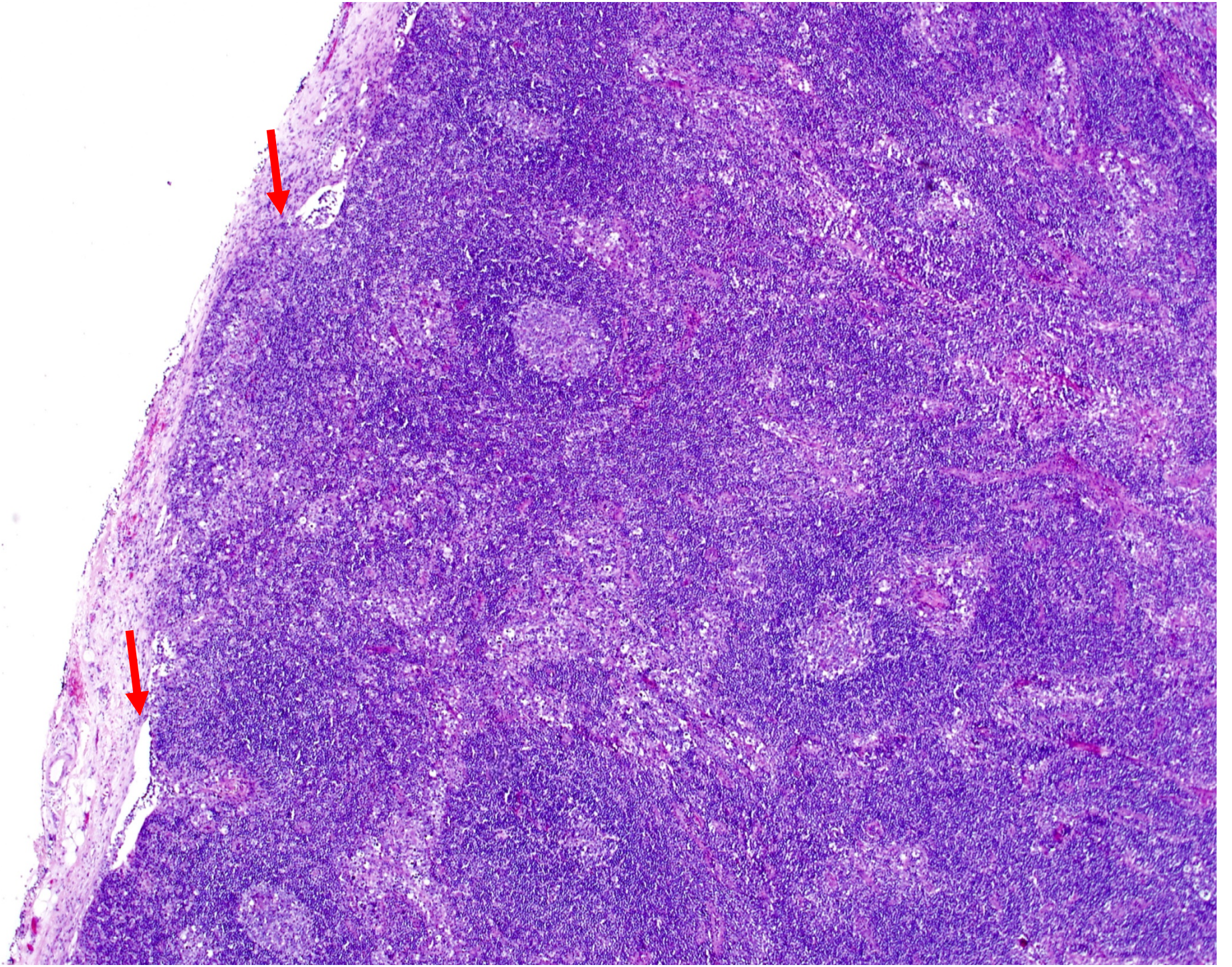




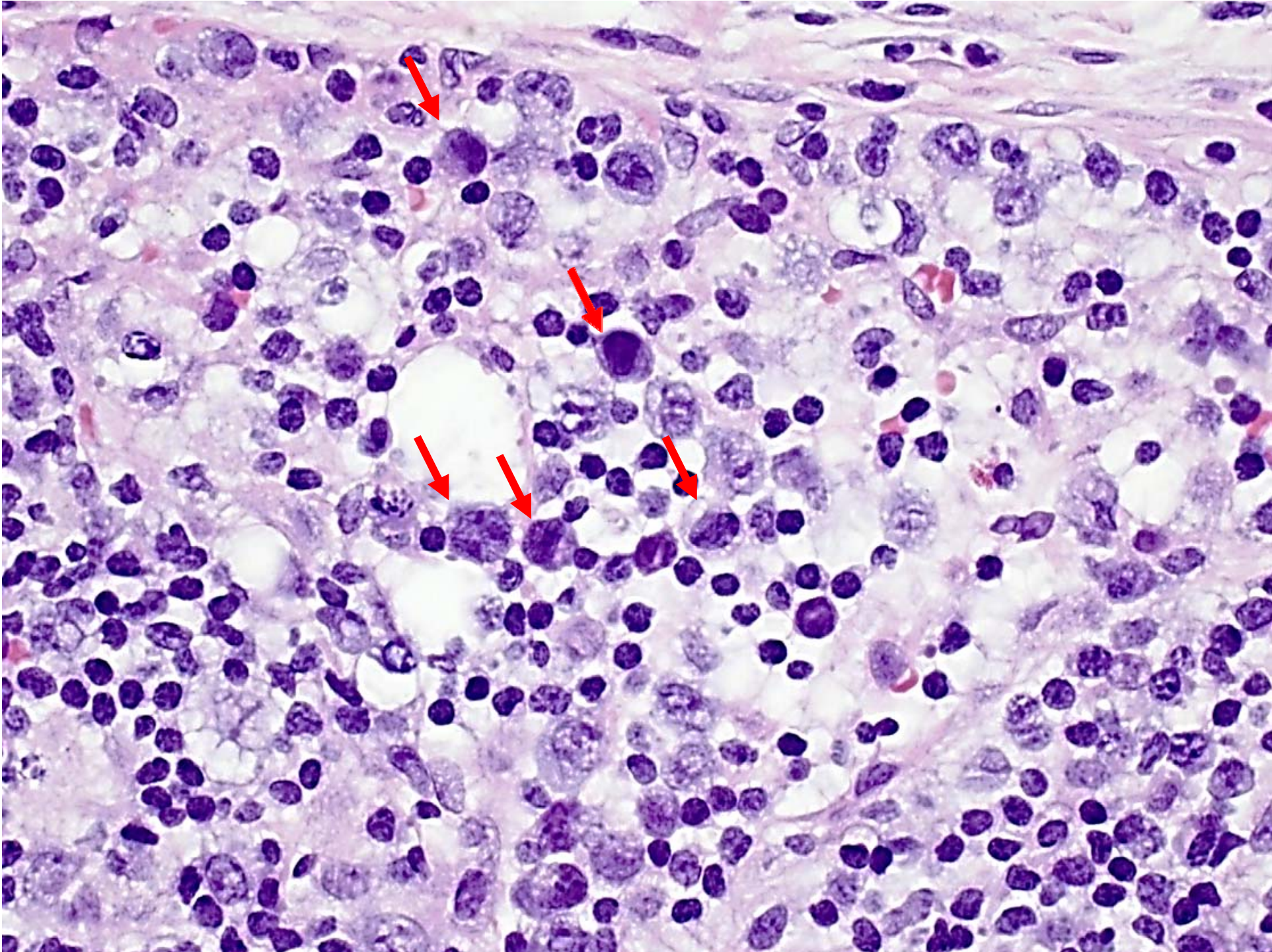




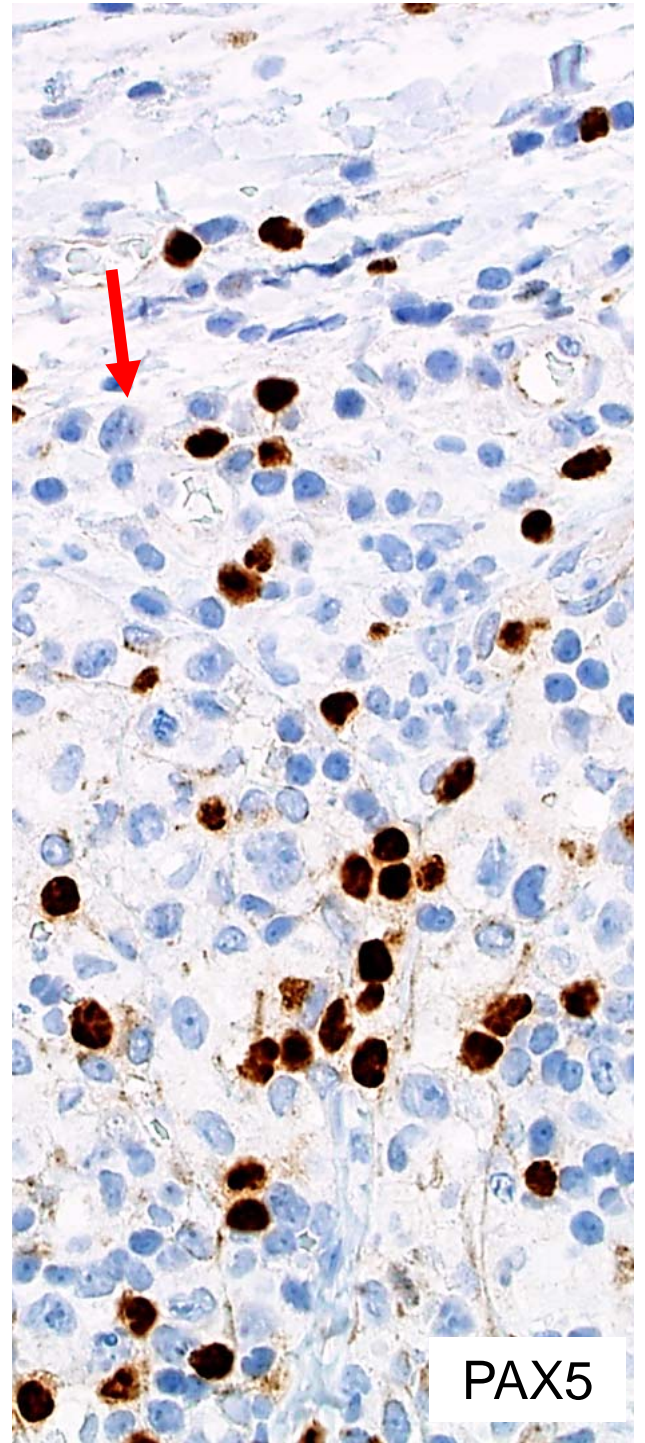
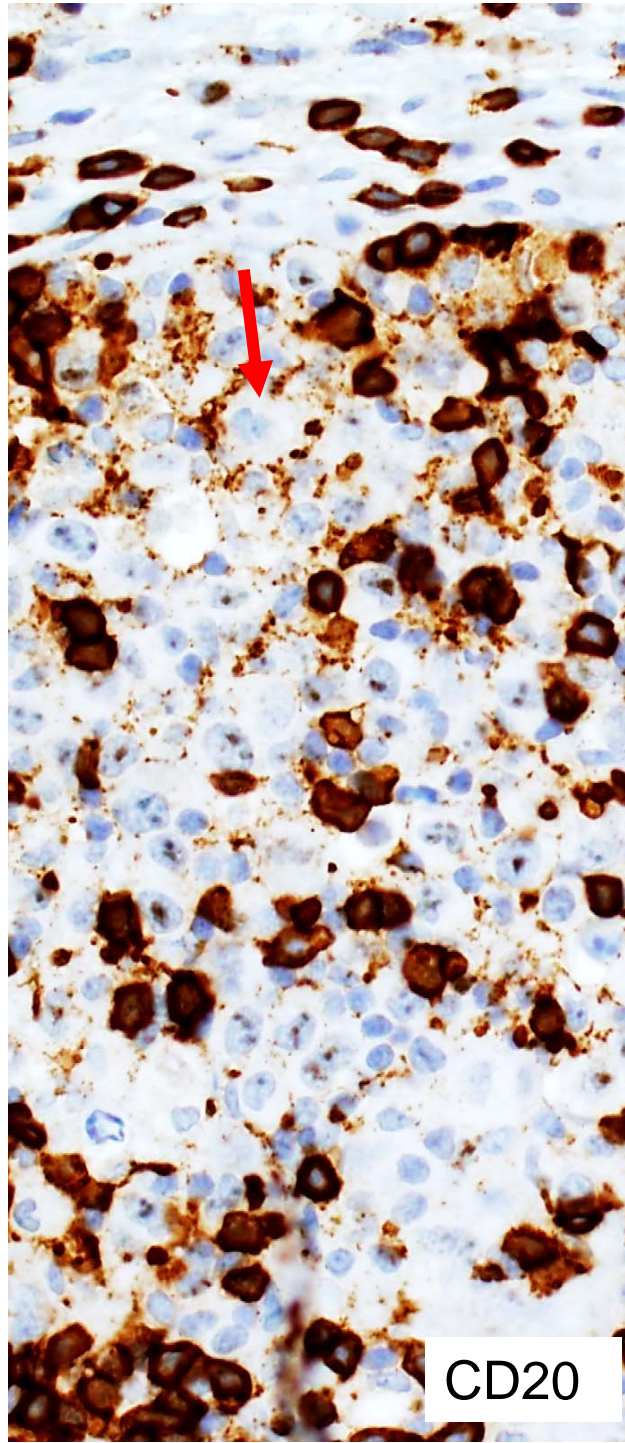
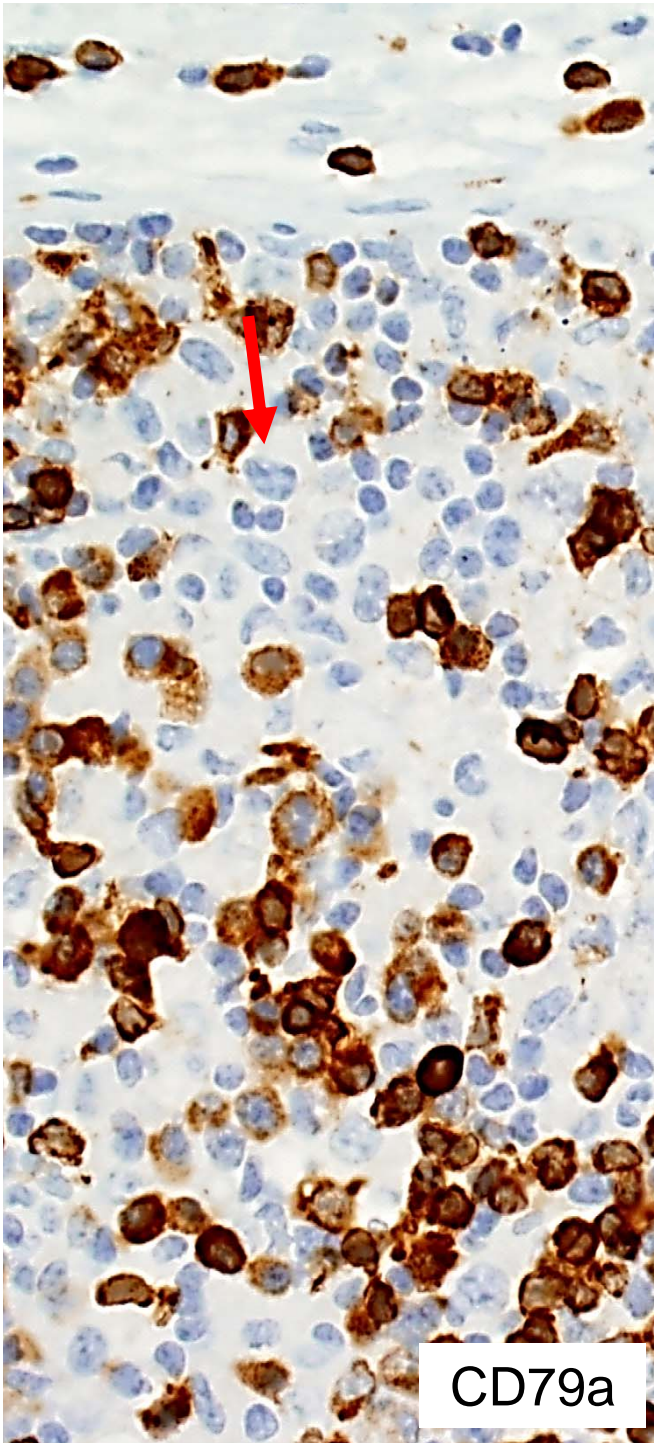




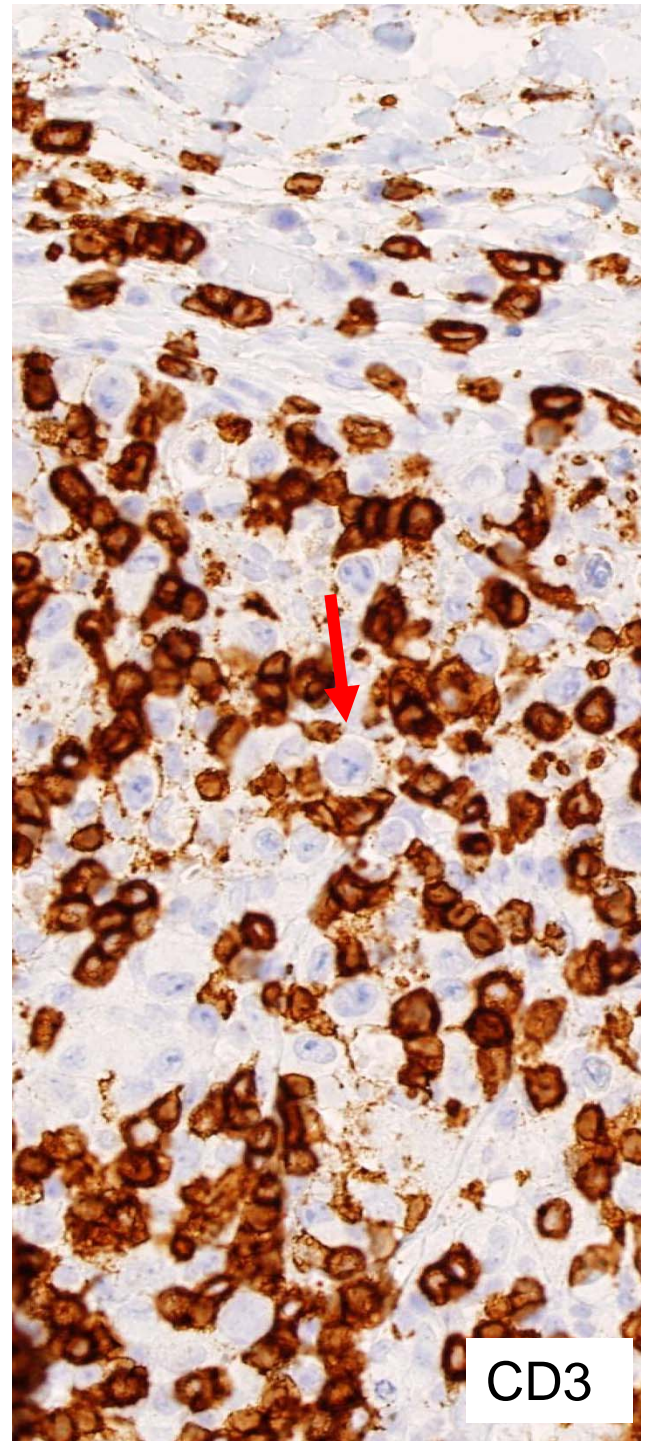
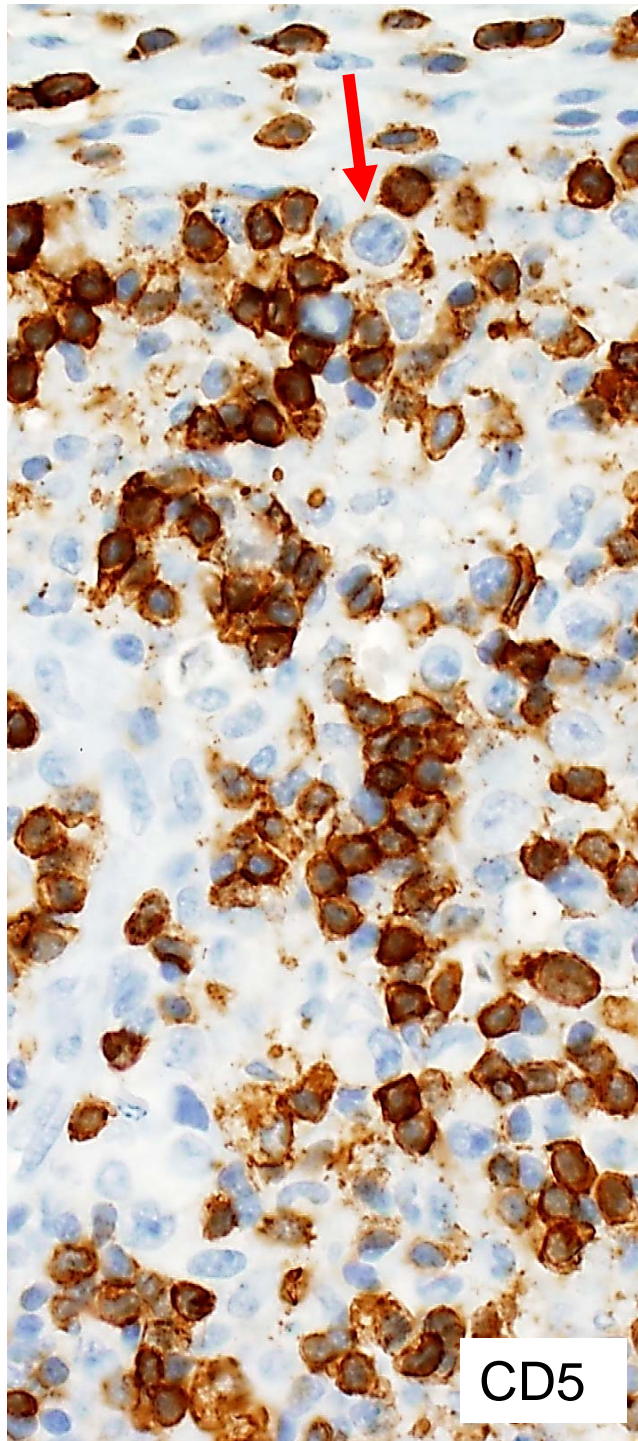
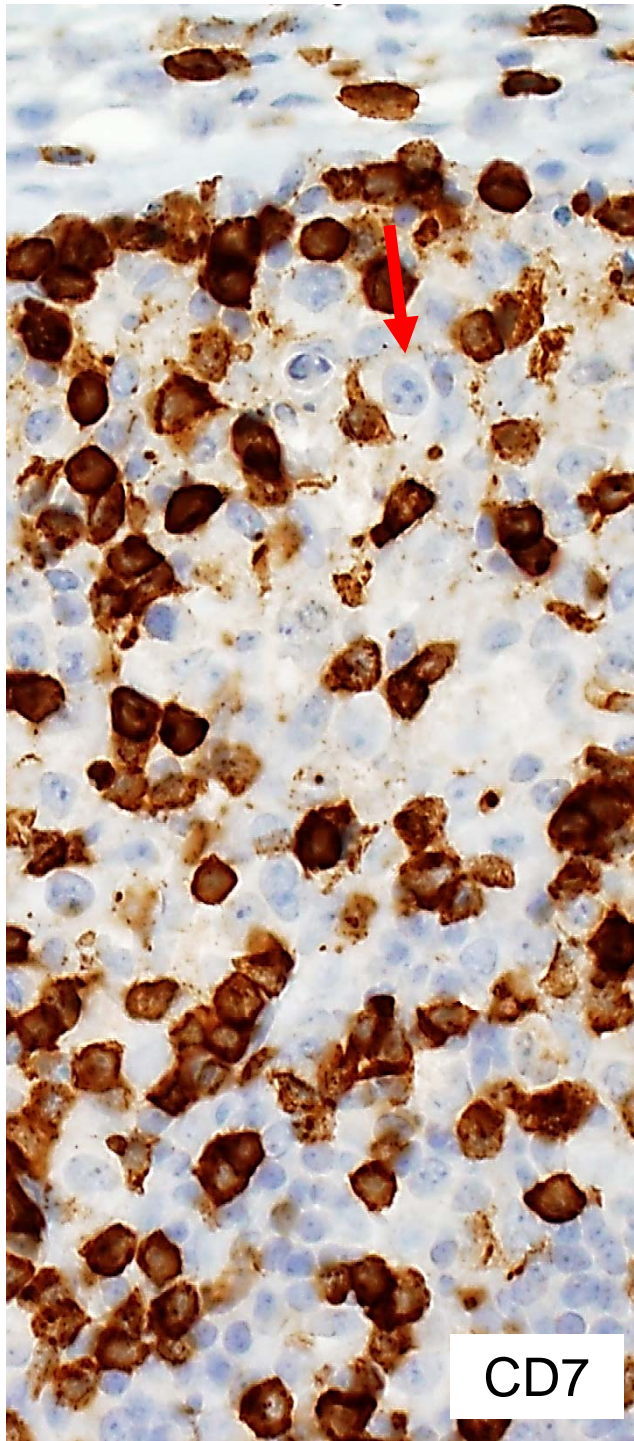




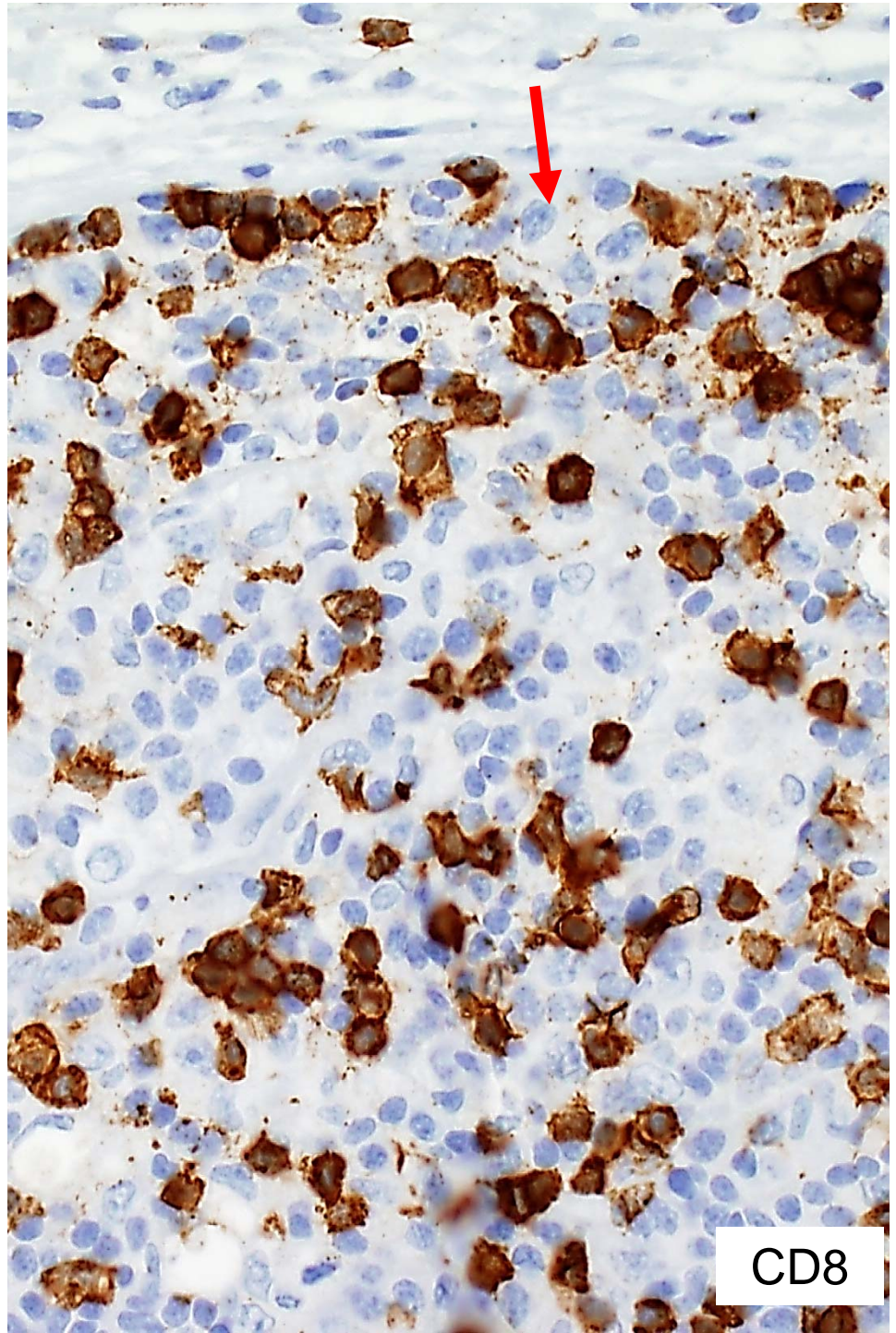
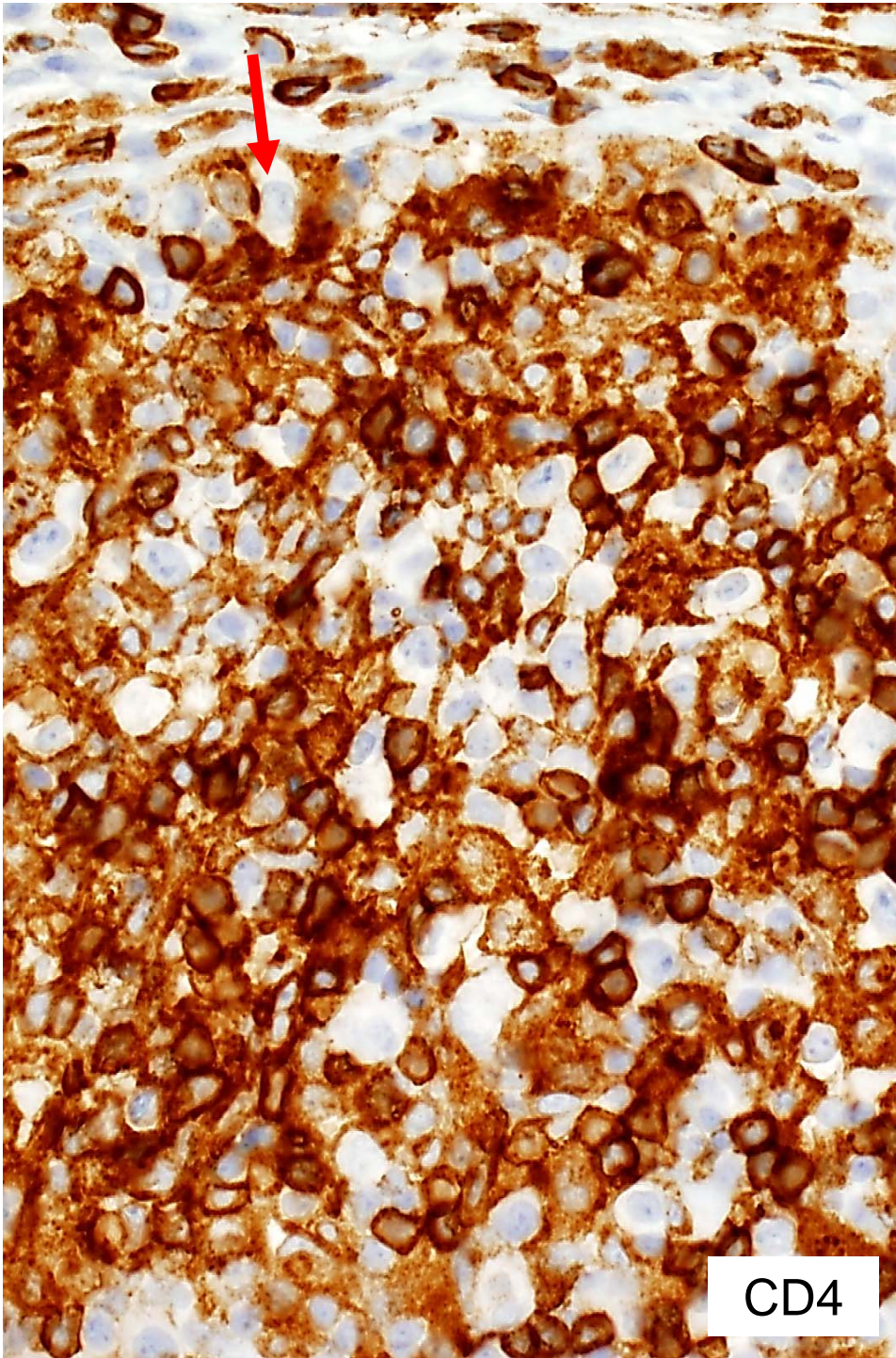




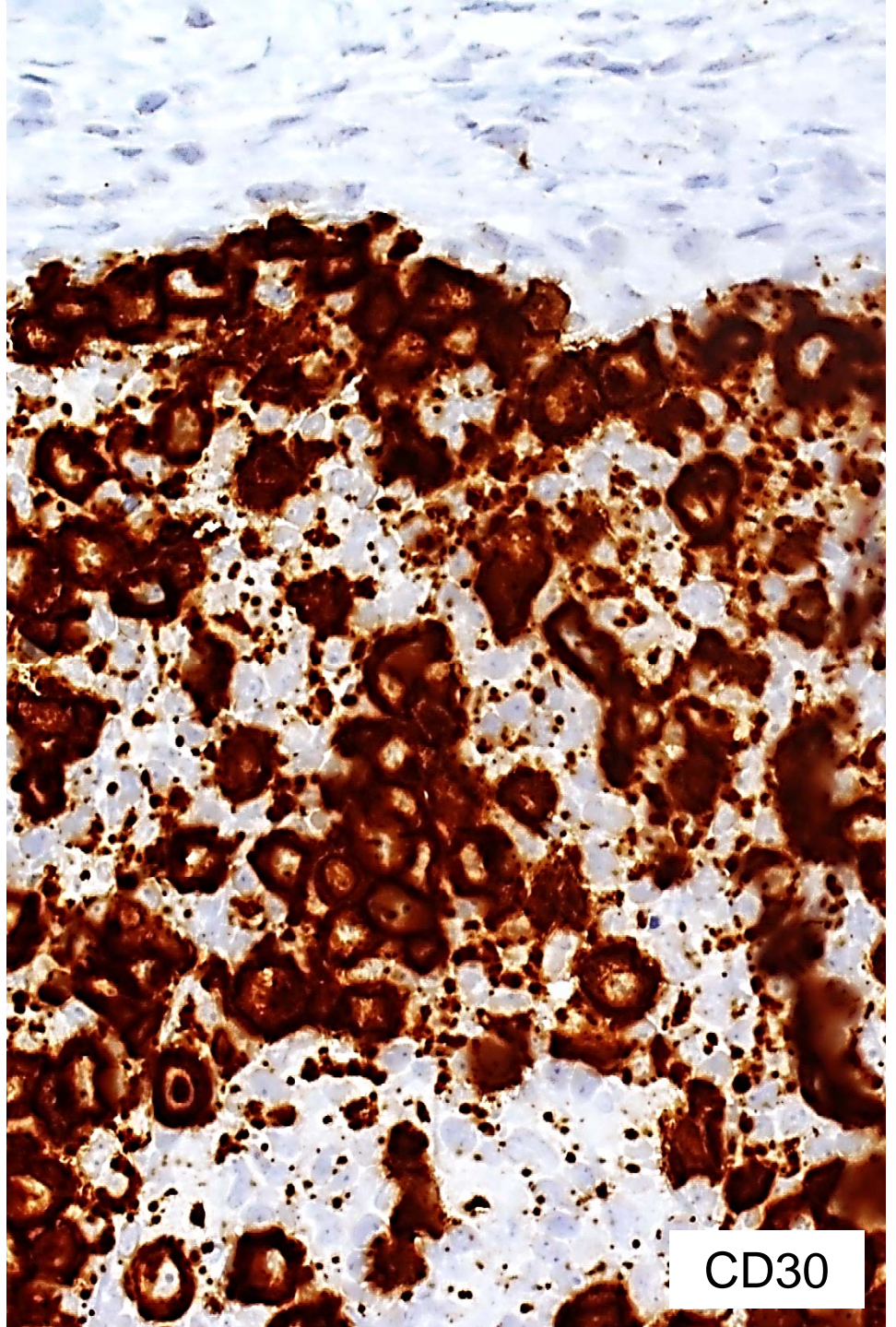
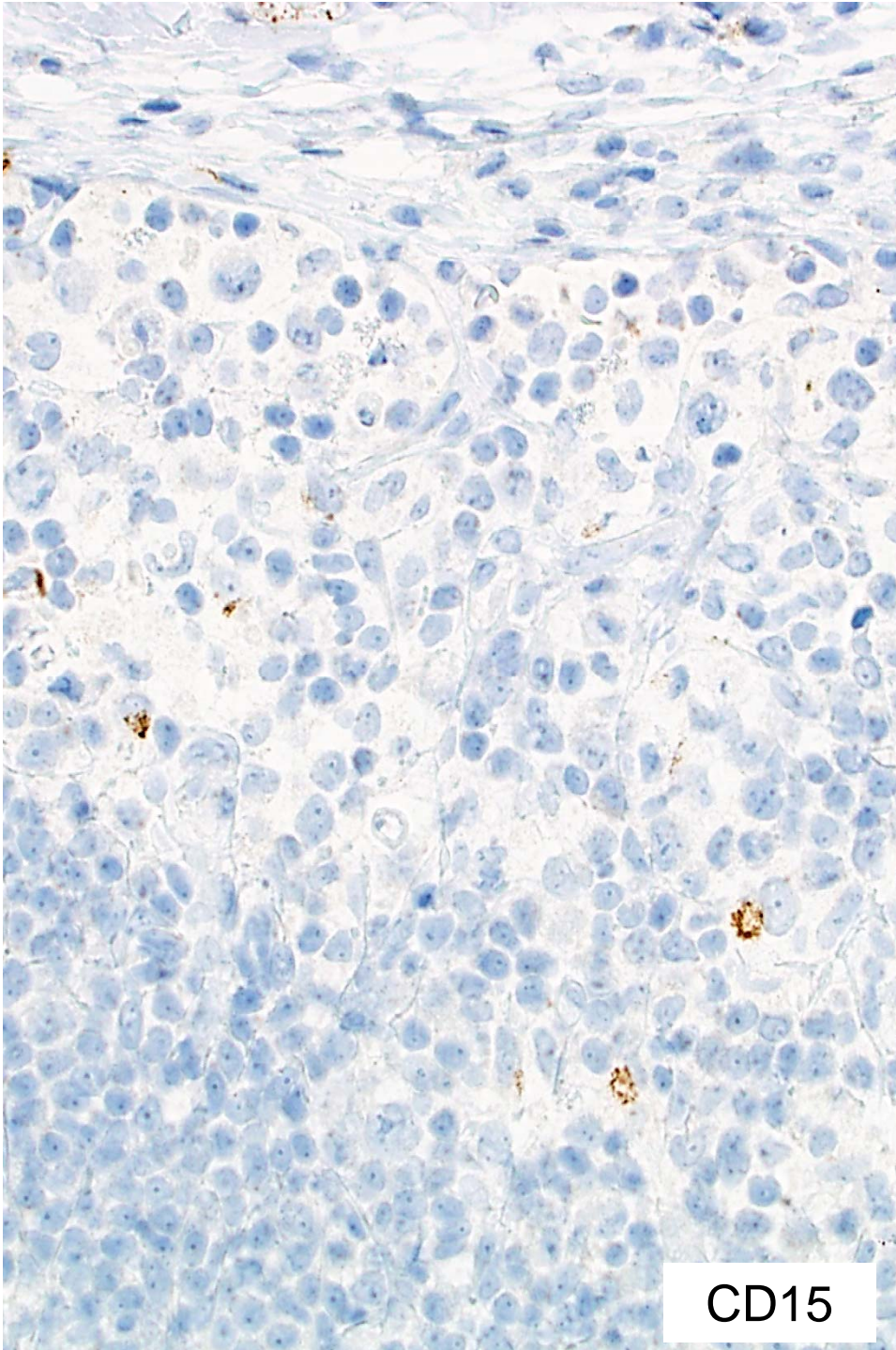




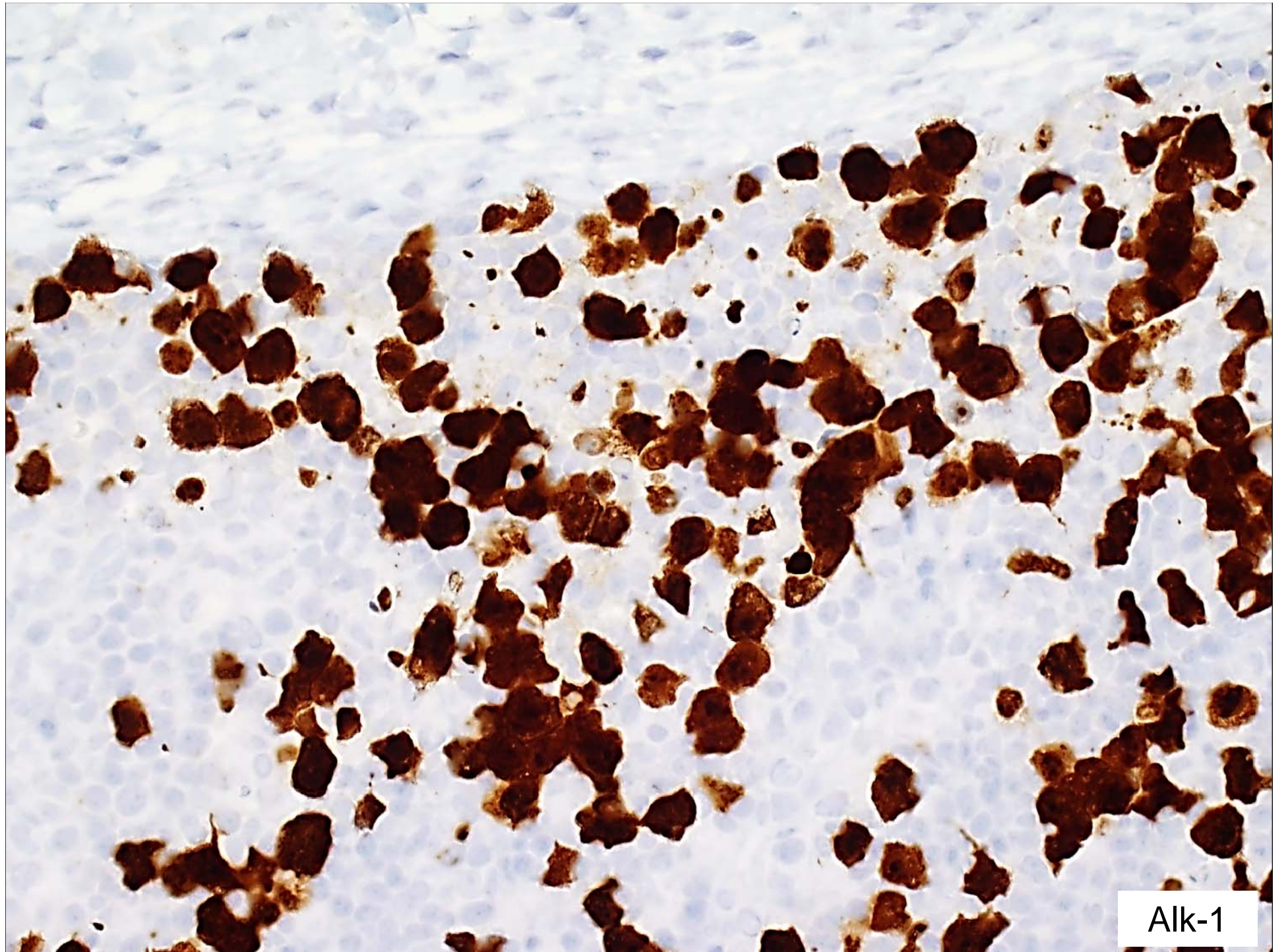






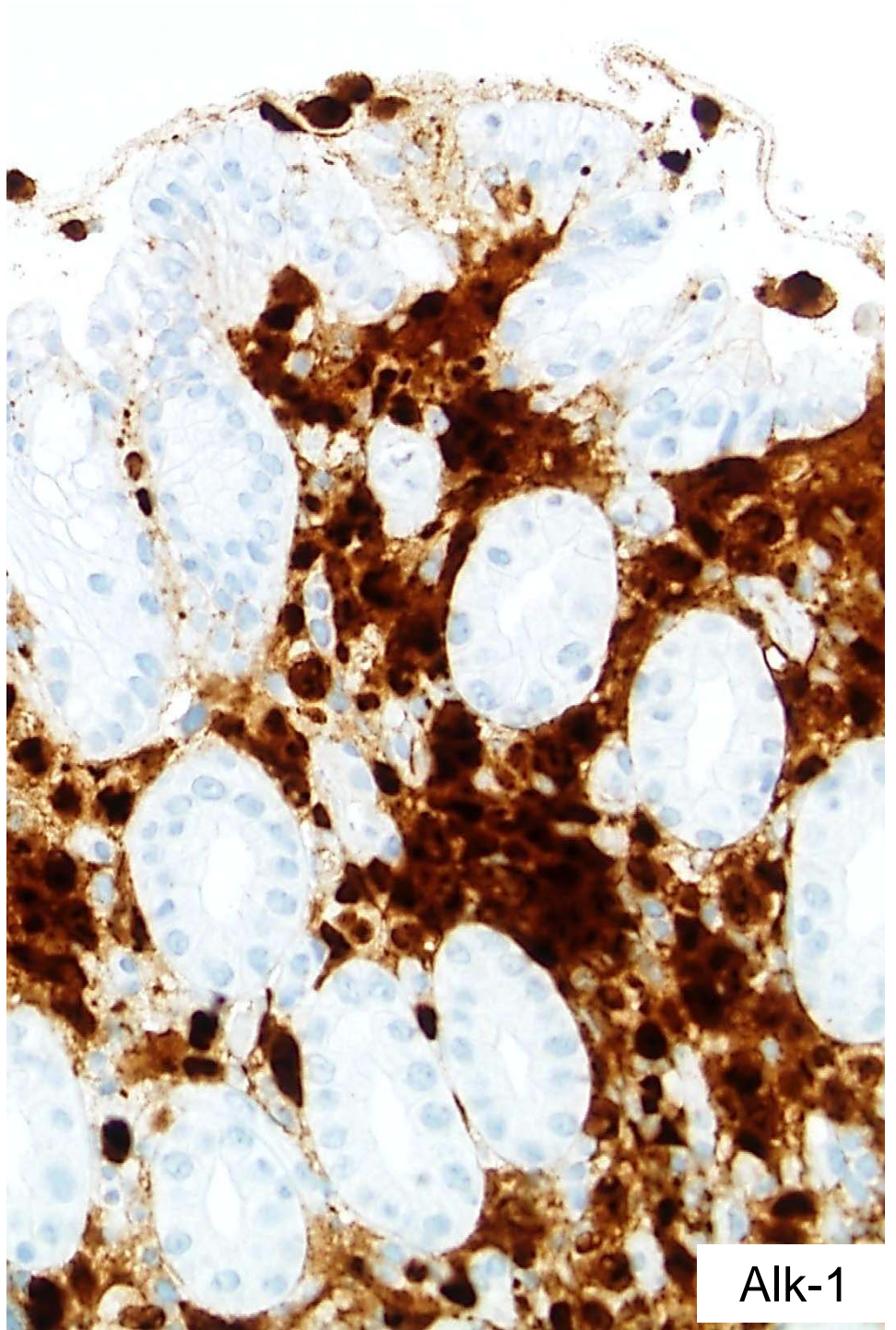
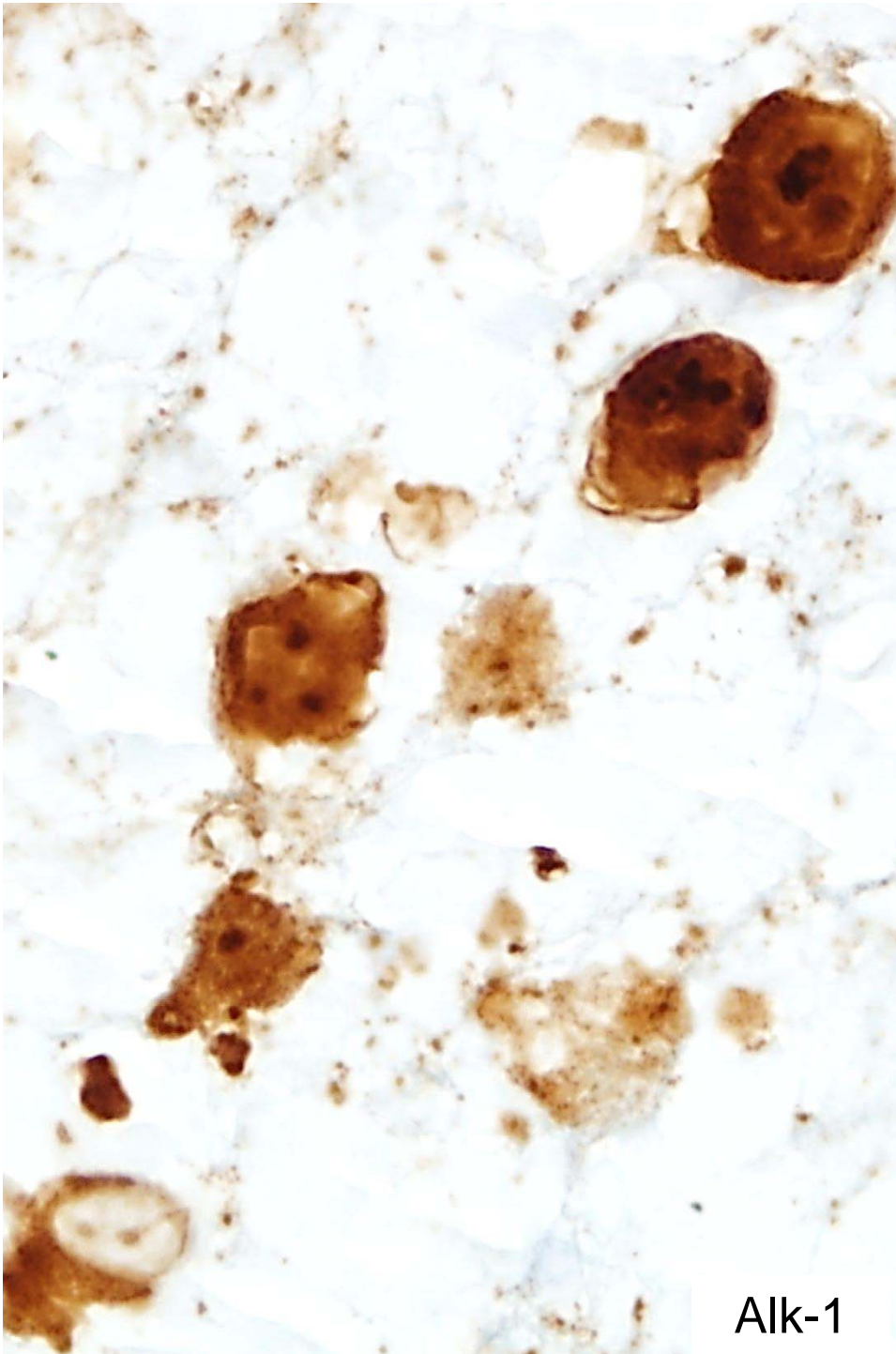






Alk-1

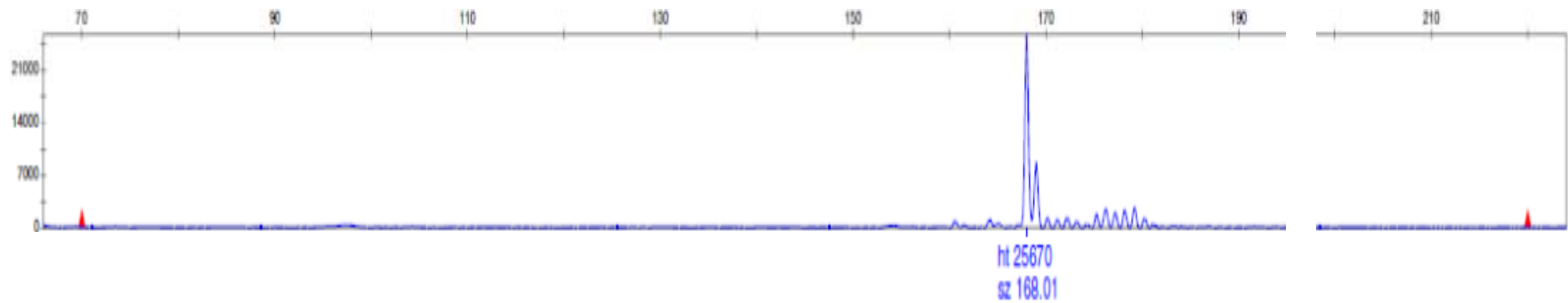
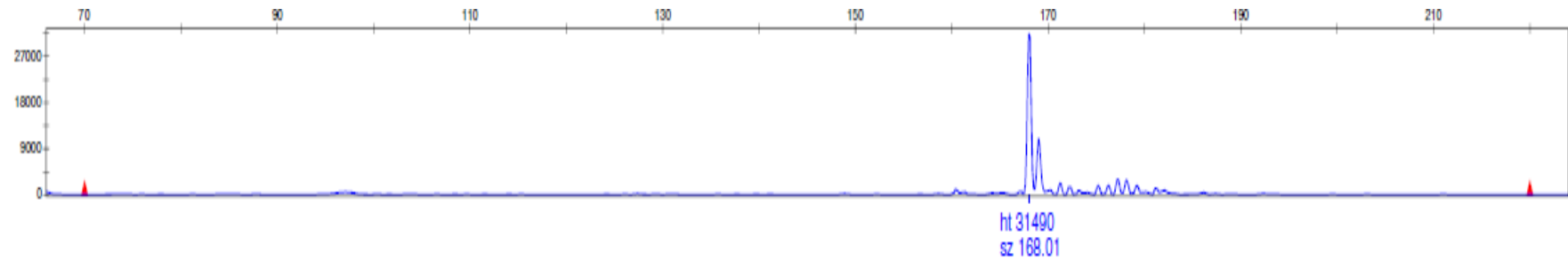


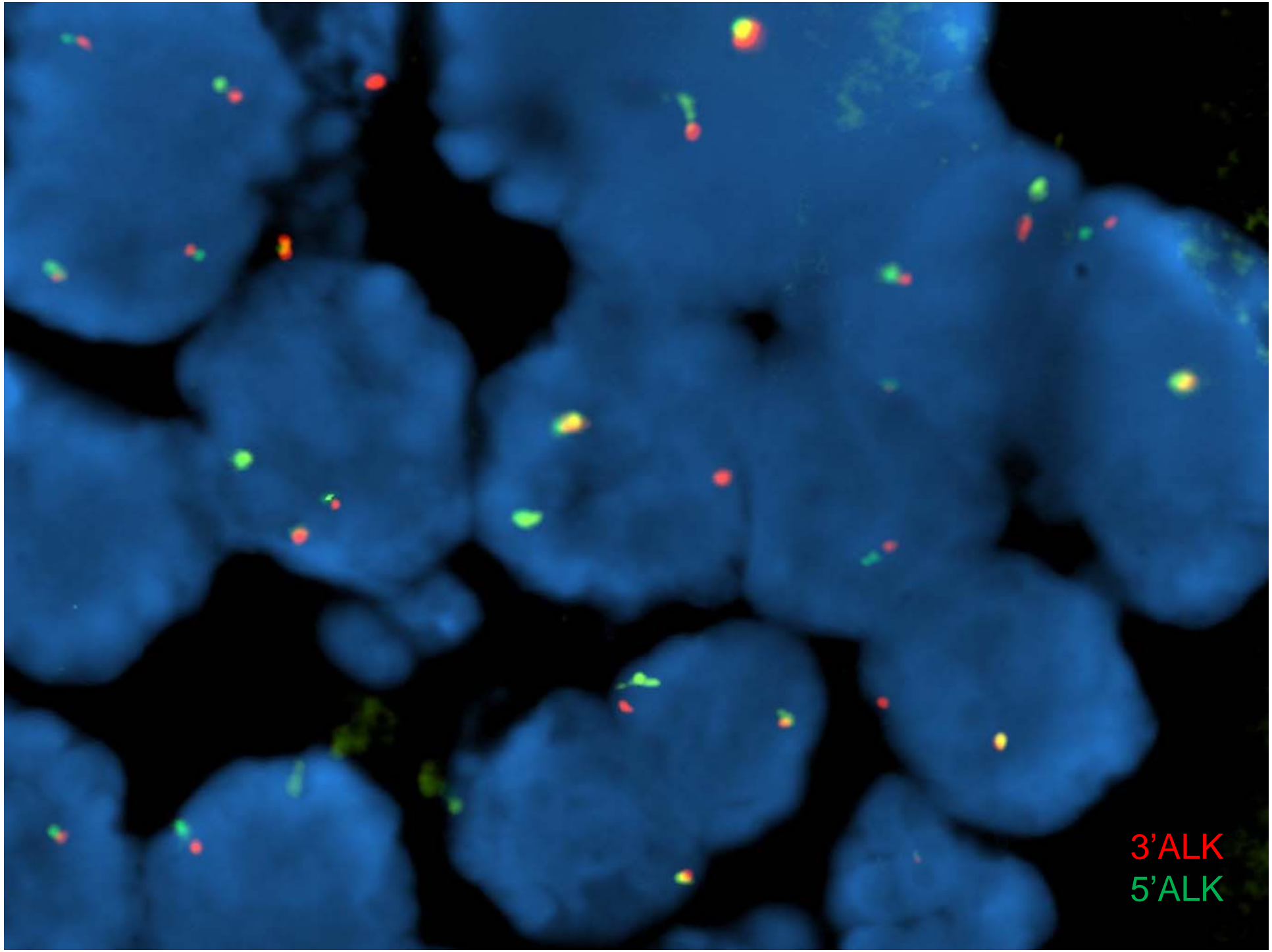


- AE1/AE3 -
- EMA +
- CD2 -
- MUM1 +
- TIA1 +
- P53 -
- Ki67 **70%**



# Reordenamiento TCR gamma





3'ALK  
5'ALK

# Diagnóstico:

LINFOMA ANAPLÁSICO ALK +  
con afectación osteoarticular, ganglionar y  
de mucosa gástrica

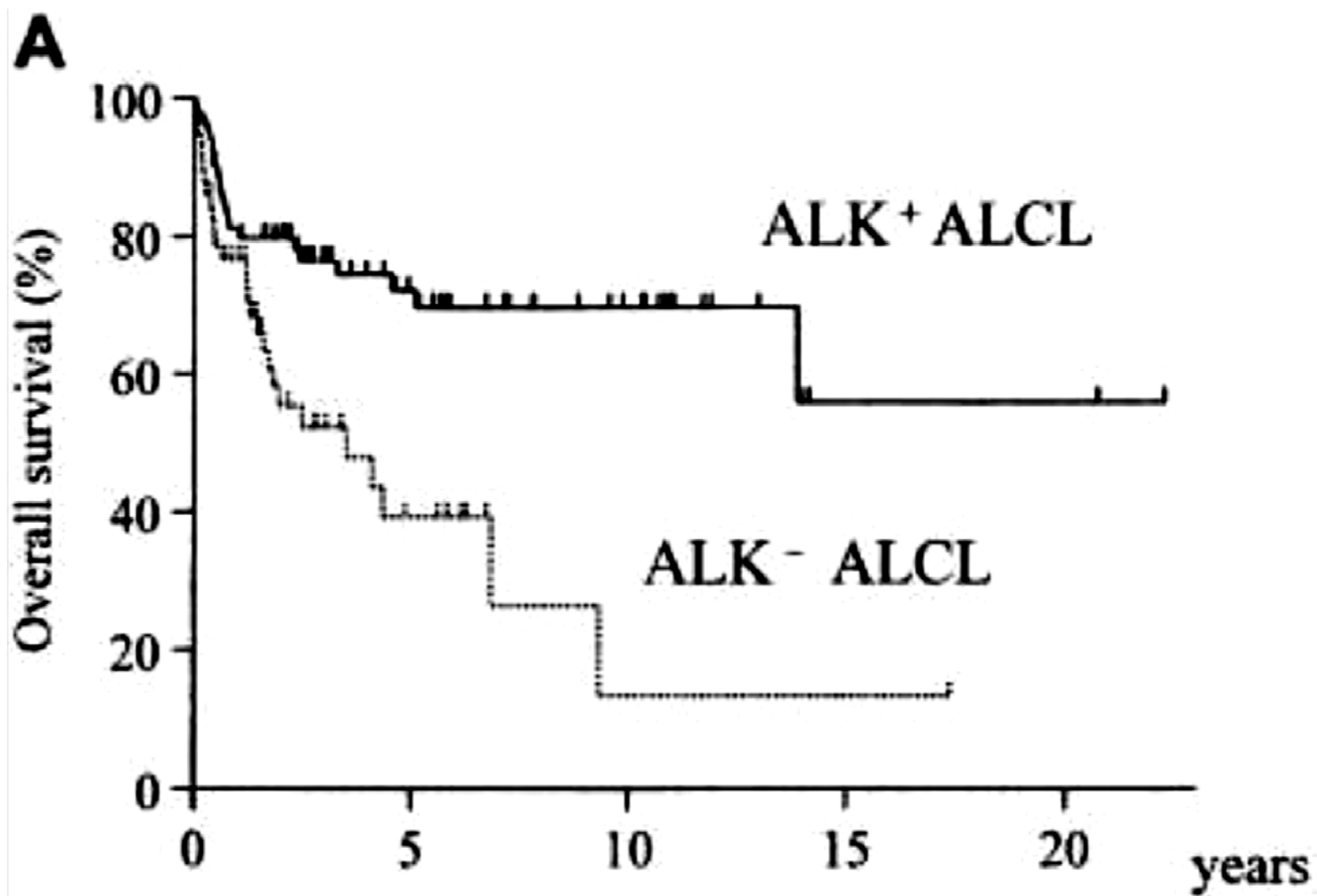
# Linfoma anaplásico de célula grande (ALCL) OMS 2008

- SISTÉMICOS:
  - ALK (+)
  - ALK (–) (\*)
  
- LINFOMA ANAPLÁSICO PRIMARIO CUTÁNEO

(\*)-Entidad provisional en la Clasificación 2008 OMS  
Anaplastic large cell lymphoma. Mason DY, Campo E, Harris NL et al. In WHO Classification of Tumors of Haematopoietic and Lymphoid Tissues.

# ALCL OMS 2008

	<b>ALK+</b>	<b>ALK-</b>
Edad	Niños o adultos jóvenes (<30)	Adultos (40-65)
Presentación clínica	Estadios avanzados, afectación extranodal (piel, médula ósea, partes blandas, ...)	Estadios avanzados, con afectación extranodal menos frecuente que ALK+
Pronóstico	Más favorable	Menos favorable



# **A Phase I Weekly Dosing Study of Brentuximab Vedotin in Patients with Relapsed/Refractory CD30-Positive Hematologic Malignancies**

Michelle A. Fanale, Andres Forero-Torres, Joseph D. Rosenblatt, et al.

Clin Cancer Res 2012;18:248-255. Published OnlineFirst November 11, 2011

---

## **Crizotinib in Anaplastic Large-Cell Lymphoma**

Carlo Gambacorti-Passerini, M.D, Cristina Messa, M.D, Enrico M. Pogliani, M.D

N Engl J Med. 2011 Feb 24;364;8

---

## **Brentuximab vedotin and crizotinib in anaplastic large-cell lymphoma.**

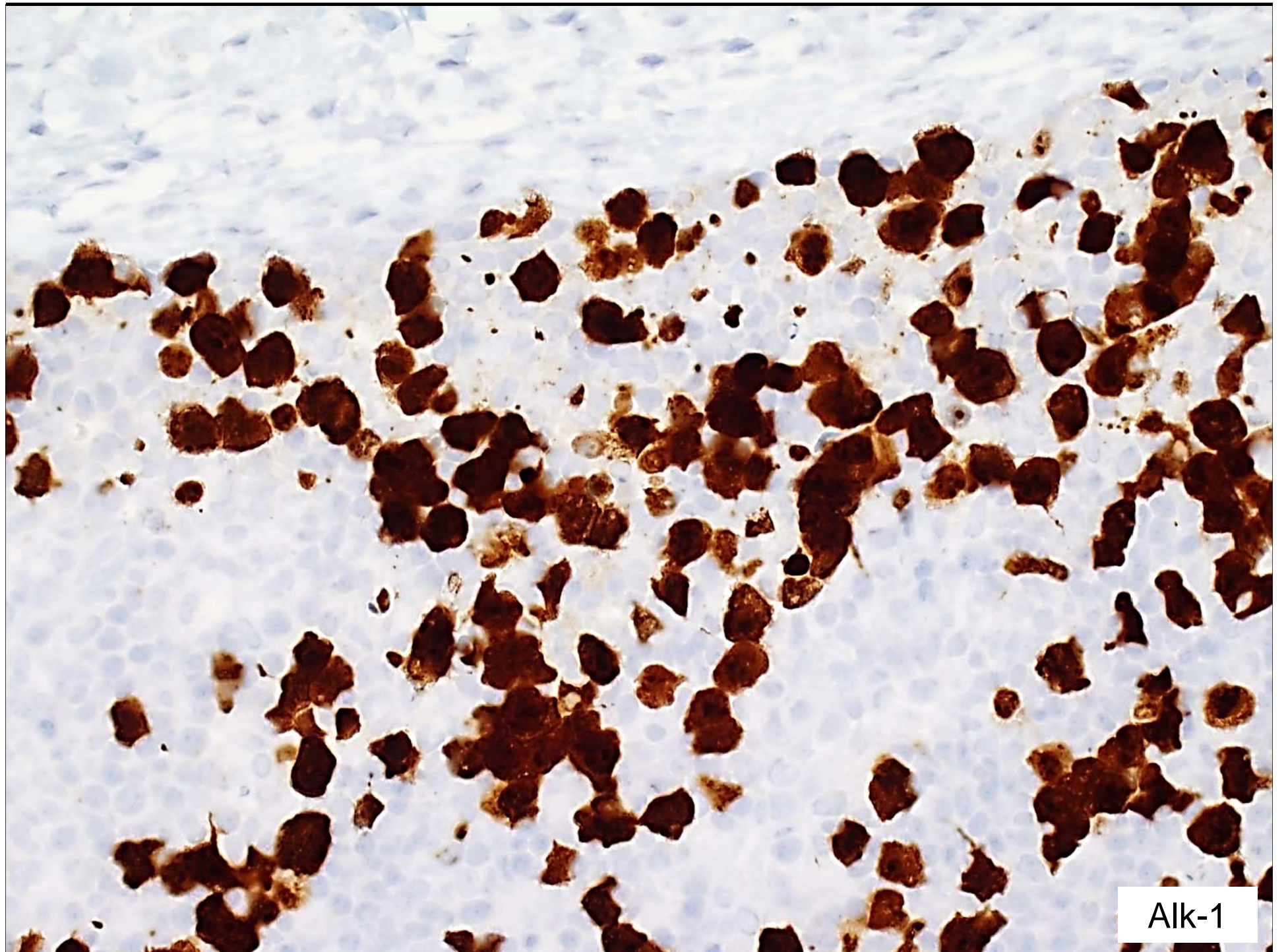
Foyil KV, Bartlett NL.

Cancer J. 2012 Sep-Oct;18(5):450-6.

- **Anaplastic lymphoma kinase (ALK):** Actividad tirosin-quinasa
- **Translocaciones de ALK en ALCL :**

<b>Translocación</b>	<b>Partner</b>	<b>Patrón de tinción de ALK</b>
t(2;5)(p23;q35)	NPM	Nuclear y citoplasmático difuso
t(1;2)(q25;p23)	TPM3	Citoplasmático difuso con intensificación periférica
t(2;3)(p23;q21)	TFG Xlong	Citoplasmático difuso
Inv(2)(p23;q35)	ATIC	Citoplasmático difuso
t(2;X)(p23;q11)	MSN	Membrana superficial





Alk-1

- Linfoma anaplásico de célula grande sistémico:
  - ALK (+)
  - ALK (–)

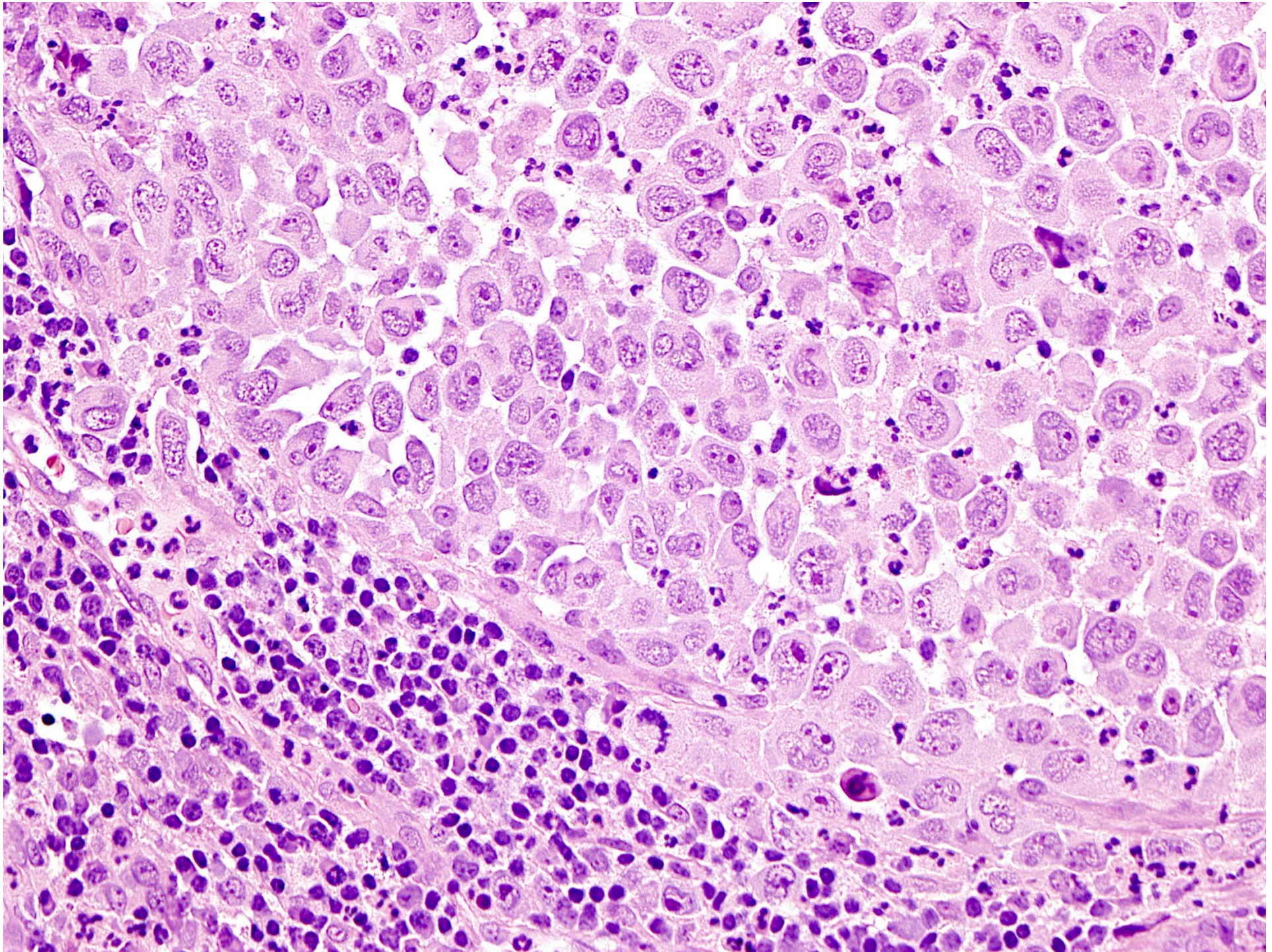
# CD30 en neoplasias no linfoides

- Mesoteliomas 40%
- Cáncer de tiroides 33%
- Cáncer anal 33%
- Melanomas 25%
- Carcinomas escamosos 25%
- Cáncer de ovario 7%
- Cáncer de mama 5%
- Cáncer de pulmón 4%
- Cáncer de páncreas 3%

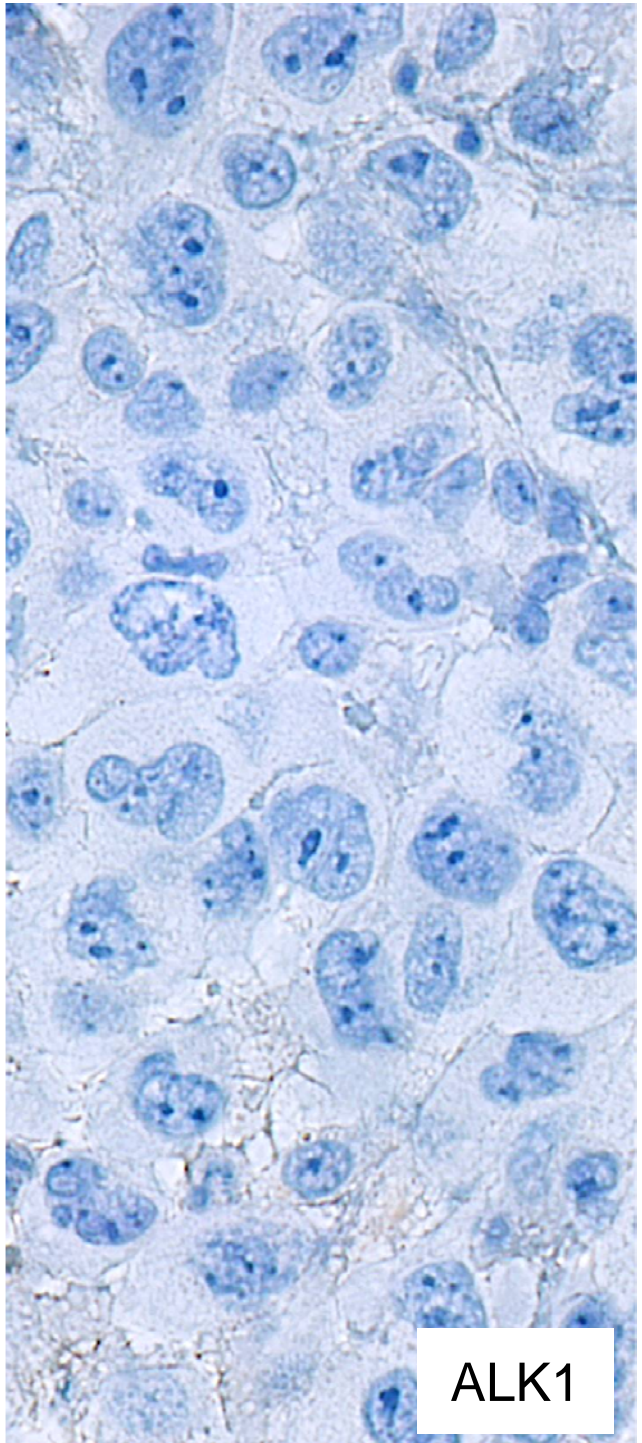
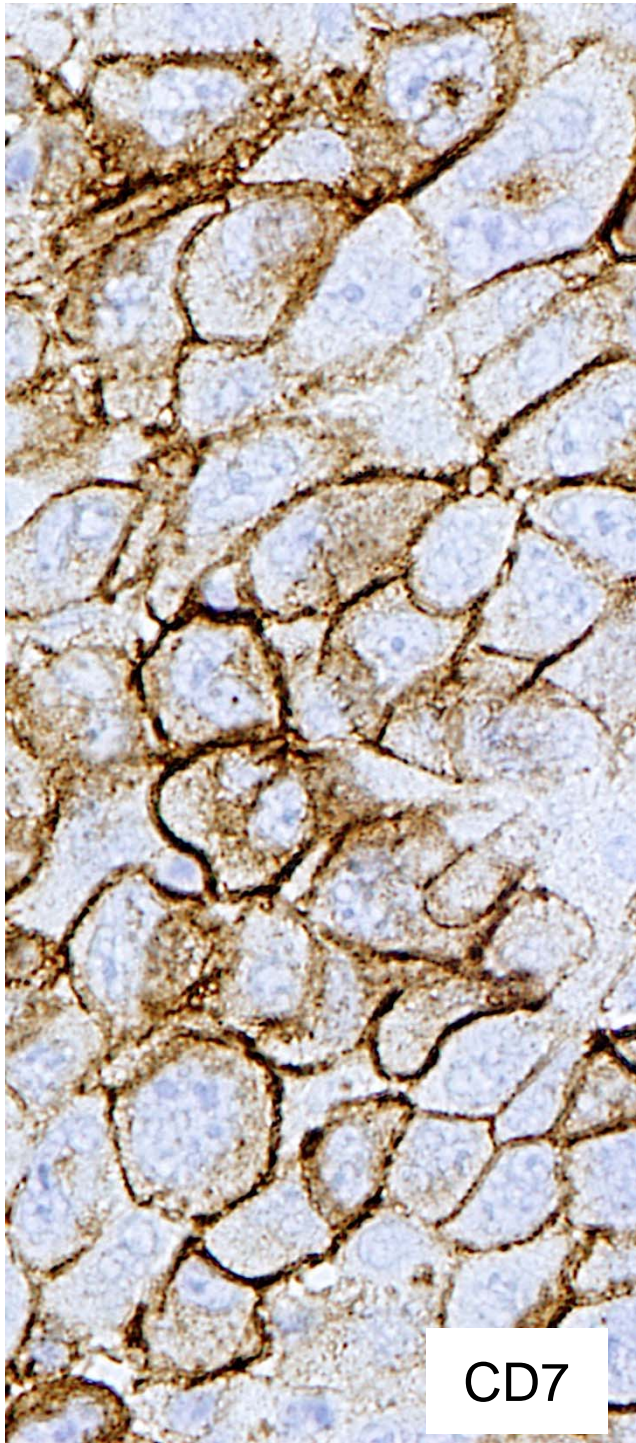
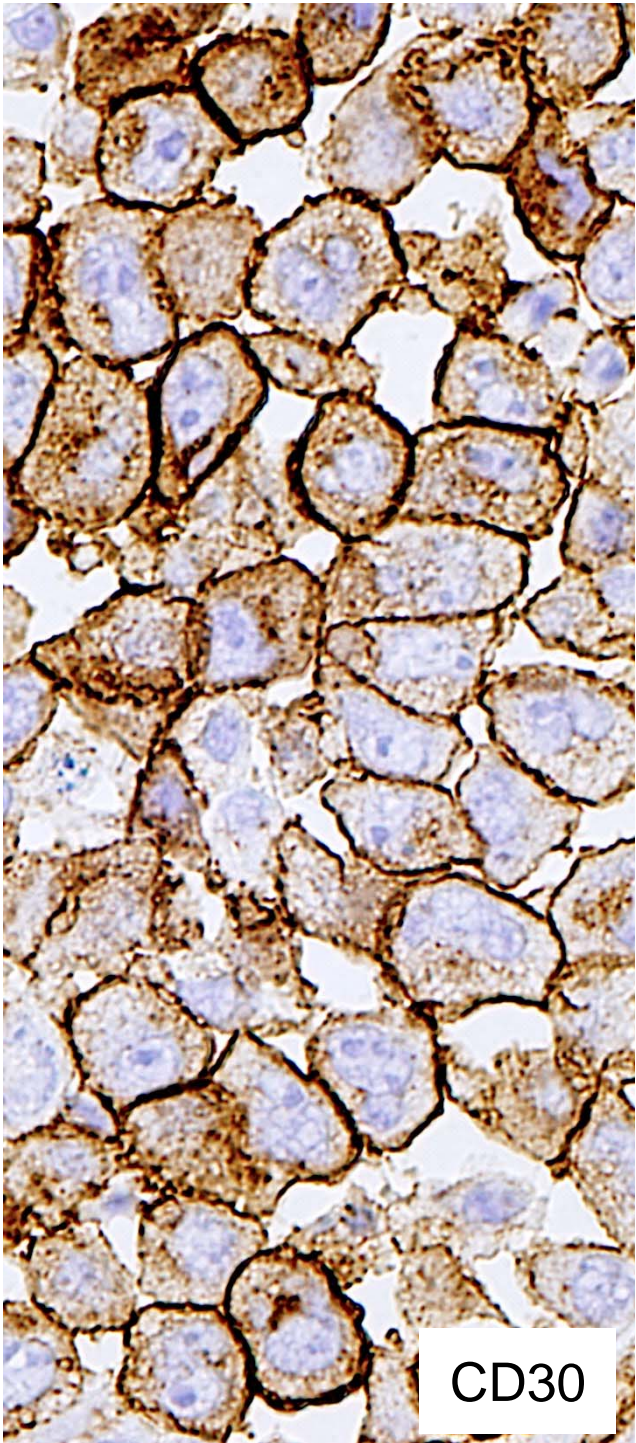
# Ag. T/NK en neoplasias no hematopoyéticas

- CD2 0%
- CD3 0%
- CD4 0%
- CD5 12'3%
- CD7 19'3%
- CD8 0%
- CD56 23,7%

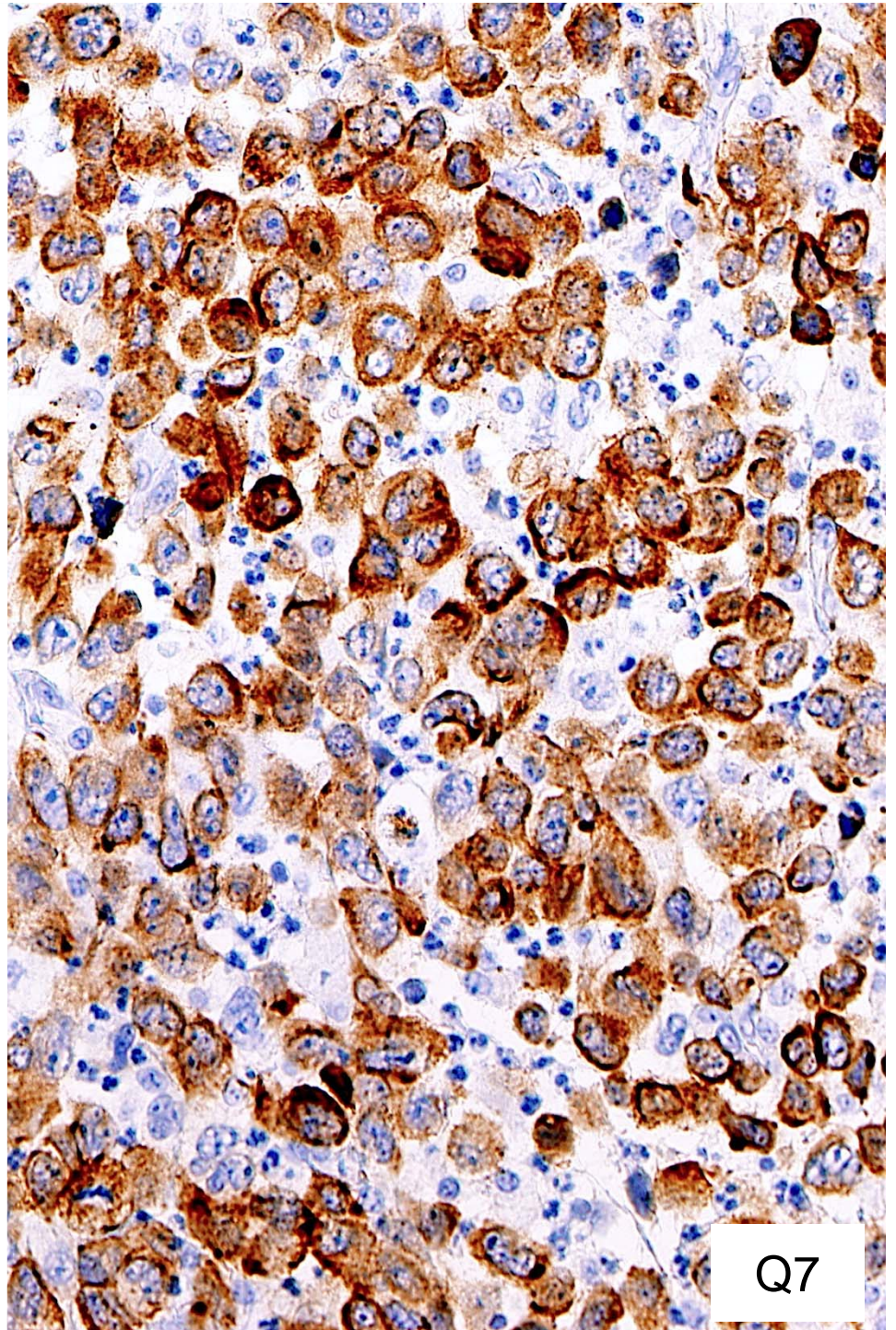
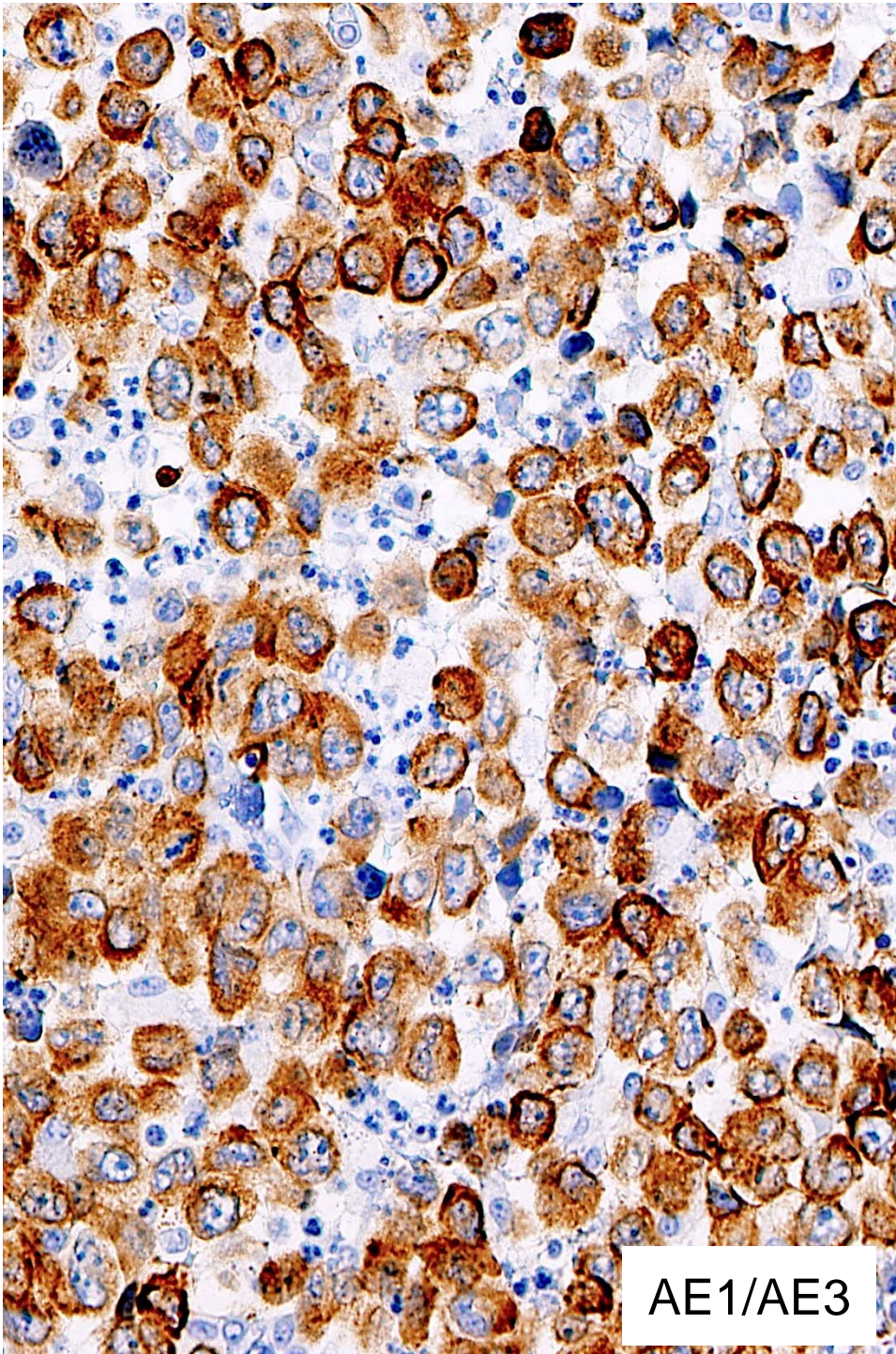




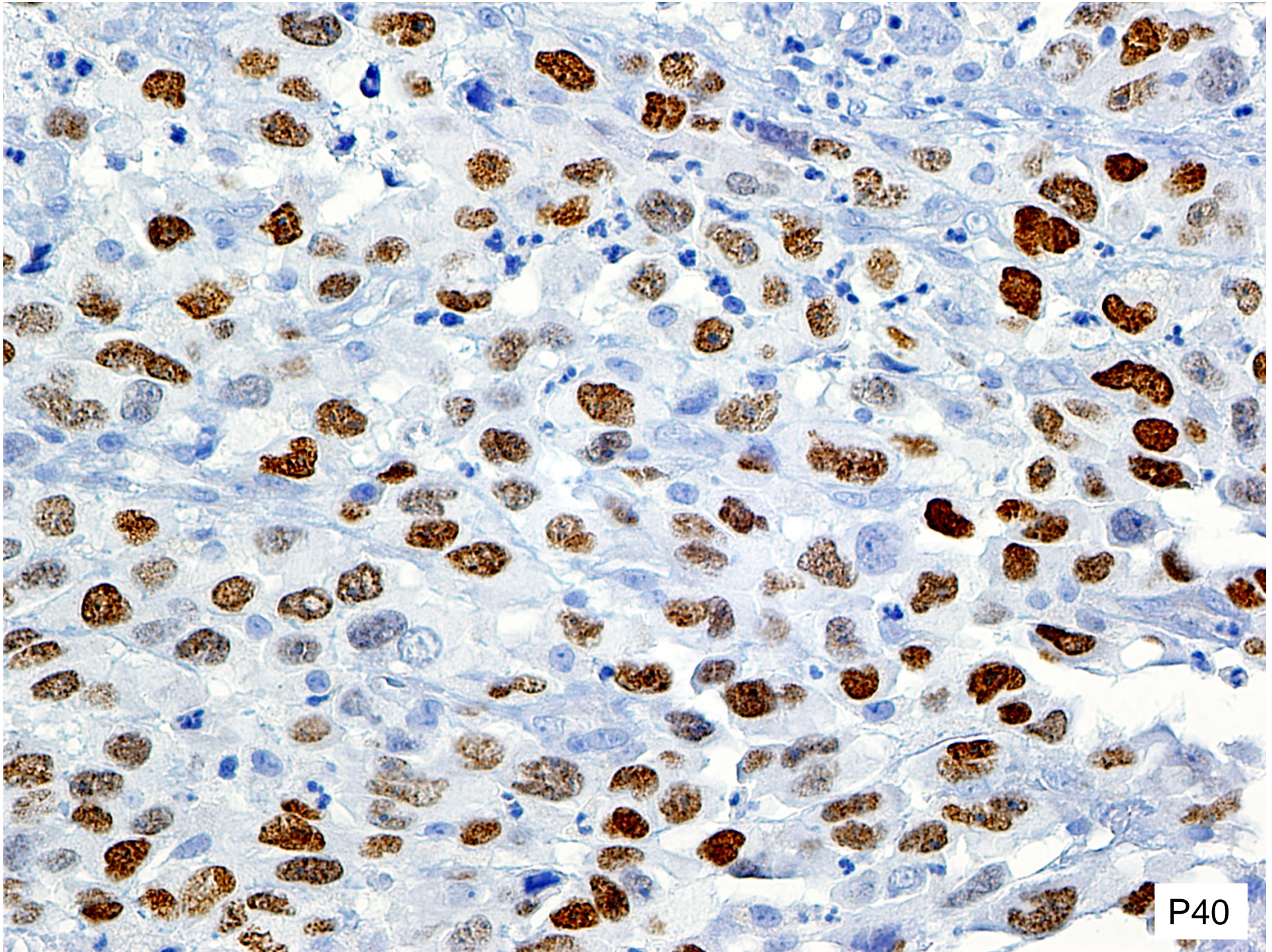












P40



